

Role of P16^{INK4a} immunoexpression in diagnostically difficult cases in cervix

Leena Dennis Joseph^{1*}, C N Sai Shalini², Pavithra V³, Lawrence D'Cruze⁴, Rajendiran S⁵

^{1,5}Professor, ^{2,3,4}Assistant Professor, Department of Pathology, Sri Ramachandra University, Porur, Chennai-116, Tamil Nadu, INDIA.

Email: leenadj@rediffmail.com

Abstract

Background/Aims: Cervical biopsies harbouring inflammatory and reactive conditions showed similar histology as that of early Cervical intraepithelial neoplasia (CIN) lesions making it difficult to distinguish both of them. This scenario paved the way for experimenting new specific biomarkers for high risk cervical lesions. p^{16INK4a} is a cell cycle regulatory protein that has a negative influence on cell proliferation by sharing a reciprocal relationship with tumor suppressor protein, retinoblastoma gene product (pRB). This pRB is inactivated by human papillomavirus (HPV) oncoprotein E7 leading to inappropriate shifting of cell cycle directly into S phase. This results in reciprocal overexpression of p16^{INK4a} which can be demonstrated immunohistochemically using monoclonal antibodies **Methods:** A total of 100 cases of cervical lesions including inflammatory lesions (n=23), CIN I (n=5), CIN II (n=5), CIN III (n=31) and invasive carcinomas (n=36) were selected. For immunohistochemistry the CIN Tec Histology kit (Mur and Mur) was used. Strong nuclear and cytoplasmic positivity was considered a positive reaction. **Results:** Of the 23 cases of chronic cervicitis, 22 cases (95.6%) were negative for P16^{INK4a} staining. Only one case was positive (4.3%) Of 5 cases of CIN I, 2 cases (40%) were positive for the stain whereas 3 cases (60%) were negative. Of the 5 cases of CIN II, 2 cases were positive (40%) and 3 cases (60%) were negative. In the CIN III group of 31 cases, 26 cases (83.8%) were positive for P16^{INK4a} staining, but 5 cases (16.1%) were negative. All the 26 cases showed a 100% full thickness positivity. In the category of Invasive squamous cell carcinoma, 29 cases (80.5%), out of the 36 showed a 100% full thickness positivity but 7 cases (19.4%) were negative. Statistical analysis was done and CHI SQUARE VALUE=45.05; P value <0.001 **Conclusions:** The use of P16^{INK4a} immunostain is a useful adjunct with Hematoxylin and Eosin (H&E) stained slides, as it aids to increase diagnostic accuracy and interobserver agreement in the diagnosis of high grade cervical intraepithelial neoplasia and carcinoma

Keywords: CIN, P16^{INK4a}, REACTIVE ATYPIA, HPV.

*Address for Correspondence:

Dr. Leena Dennis Joseph, Professor, Department of Pathology, Sri Ramachandra University, Porur, Chennai-116, Tamil Nadu, INDIA.

Email: leenadj@rediffmail.com

Received Date: 17/02/2015 Revised Date: 25/02/2015 Accepted Date: 28/02/2015

Access this article online

Quick Response Code:



Website:

www.statperson.com

DOI: 01 March 2015

INTRODUCTION

Cervical cancer is the third most common malignancy of the female genital tract and also the second most common cancer in women worldwide¹. Population wide screening by Papanicolou test identified asymptomatic women with preneoplastic lesions or early cancer of the uterine cervix

but with a substantial rate of false negative test results. Cervical biopsies harbouring inflammatory and reactive conditions showed similar histology as that of early CIN (Cervical Intraepithelial Neoplasia) lesions making it difficult to distinguish both of them. This lead to unnecessary, invasive clinical investigations and possibly overtreatment with additional costs^{2,3}. This scenario paved the way for experimenting new specific biomarkers for high risk cervical lesions. P16^{INK4a} is a cell cycle regulatory protein that has a negative influence on cell proliferation by sharing a reciprocal relationship with tumor suppressor protein, retinoblastoma gene product (pRB). This pRB is inactivated by human papillomavirus (HPV) oncoprotein E7 leading to inappropriate shifting of cell cycle directly into S phase. This functional inactivation of pRB results in reciprocal overexpression of P16^{INK4a} which can be demonstrated immunohistochemically using monoclonal antibodies⁴.

Studies on cervix show a causal relationship between high risk human papilloma virus (HR-HPV) and cervical carcinoma also including preneoplastic lesions of the cervix. These HR-HPV specifically sub types 16 and 18 exhibit a strong and diffuse nuclear and cytoplasmic immunoreactivity of P16^{INK4a} in these lesions. These two subtypes are most important clinically because studies reveal that infection by these subtypes is associated with an increased risk of cervical carcinoma^{5,6}. Low risk HPV subtypes, 6 and 11 express focal and weak P16^{INK4a} immunohistochemical reactivity and are not associated with an increased risk of cervical carcinoma. Various reviews have demonstrated an overall poor interobserver agreement in the histological grading and diagnosis of CIN lesions. It has been observed that invasive carcinomas and to a great extent high grade CIN lesions were recognized well on the routine stains. Significant disagreement was noted in differentiating CIN I lesions from reactive squamous proliferation including squamous metaplasia, reserve cell hyperplasia, microglandular hyperplasia and inflammatory conditions such as chronic cervicitis^{7,8}. P16^{INK4a} immunostain has been proposed as a possible supplementary biomarker for cervical carcinomas and high grade CIN lesions (CIN 2/CIN 3). Significant expression of P16^{INK4a} was found to be restricted to CIN 2/CIN 3, CIN 1 associated with high-risk human papillomavirus, or cervical cancer. Reactive and inflammatory lesions showed negative or nonspecific background staining with P16^{INK4a} immunostain. Therefore P16^{INK4a} immunostain helps to reduce interobserver variability in the histopathologic interpretation of cervical biopsy specimens, reduces false-negative and false-positive biopsy interpretation and thereby significantly improve cervical (pre)-cancer diagnosis⁹. So we aim to study the expression of P16^{INK4a} in non neoplastic, dysplastic and neoplastic cervical lesions and to correlate the intensity and extent of positivity with the grade of the lesions.

MATERIAL AND METHODS

Institutional Ethics committee clearance was obtained before starting the study. Tissue samples-Biopsy samples were collected from an archive of formalin fixed, paraffin embedded cervical tissues of a histopathological diagnostic laboratory. A total of 100 cases of cervical lesions including inflammatory lesions (n=23), CIN I(n=5), CIN II(n=5), CIN III(n=31) and invasive carcinomas(n=36) were selected. For all the samples hematoxylin and eosin stained sections were reviewed by two qualified pathologists. All the specimens were classified as either normal cervix, CIN I,II,III and invasive carcinomas.

Immunohistochemistry

Serial sections (4 micrometer thick) of formalin fixed and paraffin embedded biopsy samples were cut and processed for immunohistochemical analysis. Sections were immersed in xylene to remove paraffin and then rehydrated through graded alcohol. For immunohistochemistry the CIN Tec Histology kit (Mur and Mur) was used. Epitope retrieval was done by pressure cooker for 10 minutes. Next it was transferred to the Epitope Retrieval solution at room temperature (20-25 degree Celsius) for 20 minutes. The slides were then incubated with 200 microlitres peroxidase blocking reagent for 5 minutes. After this, the slides were incubated with Mouse anti human P16^{INK4a} for 30 minutes. After 5 minutes in wash buffer, the slides were incubated with 200 microlitres visualisation reagent for 30 minutes. Then again it went through wash buffer. At the end, the slides were incubated with 200 microlitres of substrate chromogen solution (DAB) for 10 minutes, then it was rinsed in deionised water. Then the sections were counterstained with hematoxylin and mounted.

Interpretation of P16^{INK4a} staining

Immunostaining of the formalin fixed, paraffin embedded sections were reviewed by two independent observers. Strong nuclear and cytoplasmic positivity was considered a positive reaction.

The staining pattern of P16^{INK4a} was classified as:

1. Negative, if there were no positive cells or <1% of cells were positive.
2. Diffuse lower one third positive, if positive cells lay in continuity with each other in the lower 1/3rd of a broad area of epithelium.
3. Diffuse lower two third positive, if positive cells lay in continuity with each other in the lower 2/3rd of a broad area of epithelium.
4. Diffuse full thickness, if positive cells lay in continuity with each other and involved the full thickness of a broad area of epithelium.

RESULTS

A total of 100 cases were included in the study. There were twenty three cases of chronic cervicitis, 5 cases of CIN I, 5 cases of CIN II, 31 cases of CIN III and 36 cases of invasive squamous cell carcinoma (Table 1). Of the 23 cases of chronic cervicitis, 22 cases (95.6%) were negative for P16 staining. Only one case was positive (4.3%). Of 5 cases of CIN I, 2 cases (40%) were positive for the stain whereas 3 cases (60%) were negative. Of the 5 cases of CIN II, 2 cases were positive (40%) and 3 cases (60%) were negative. In the CIN III group of 31 cases, 26 cases (83.8%) were positive for P16^{INK4a} staining, but 5 cases (16.1%) were negative. All the 26 cases showed a 100% full thickness positivity. In the category of Invasive squamous cell carcinoma, 29 cases (80.5%), out of the 36

showed a 100% full thickness positivity but 7 cases (19.4%) were negative (Figure 1) The staining pattern also was noted in the lower 1/3rd to 2/3rd of the epithelium in all the positive cases of CIN I and II. However it showed a strong full thickness positivity in all the cases of CIN III and invasive Squamous cell carcinoma. Of the 23 cases of chronic cervicitis, 22 cases were negative for P16^{INK4a}. There was one case with P16^{INK4a} staining in the lower 2/3rd of the epithelium. This case was diagnosed as chronic cervicitis on light microscopy. Of these 22 cases there were 6 cases, which were given as chronic cervicitis with reactive atypia and squamous metaplasia. However P16^{INK4a} staining was negative in all of these 6 cases. Of the 5 cases of CIN I, 3 cases were found to be negative for P16 staining. This could be attributed to the overdiagnosis of CIN I in cases with a reactive atypia which was focal. An adjacent focus of ulceration and inflammatory granulation tissue with reactive atypia can be misinterpreted as CIN I. Negative staining pattern with P16^{INK4a}, proves useful to rule out a CIN I and thus prevent overtreatment for the patient. Of the 5 cases with a light microscopic diagnosis of CIN II, 3 cases were negative for P16 staining, which could be attributable to the above reasons. However strong and diffuse staining

was noted in almost all the cases of CIN III(Figure 2 &3) and squamous cell carcinoma. In 5 cases of CIN III and 7 cases of squamous cell carcinoma the staining pattern was negative. This could be because of an over diagnosis of CIN III in those 5 cases. It could be a CIN III without the association of Human Papilloma Virus infection. The 7 cases of Invasive SCC with a negative P16^{INK4a} stain could be either because of a non HPV cause or the doubt about the antigen integrity. In 23 inflammatory lesions of the cervix, majority (96.6%) showed no staining for P16^{INK4a}. Only one case showed positivity for P16^{INK4a} in the lower 2/3rd of the epithelium 5 cases each of CIN I and CIN II were studied for P16^{INK4a} expression. 2 cases (40%) in each category showed positive staining while the other 3 cases (60%) showed negative staining. In 26(83.8%) of 31 cases of CIN III full thickness P16^{INK4a} positivity was noted. Negative staining pattern was observed in 5 (16%) cases. In the group of invasive carcinomas, 29 cases (80.5%) showed strong and full thickness positivity with P16^{INK4a} antibody while 7 cases (19.4%) showed negative pattern.

STATISTICAL ANALYSIS: A statistical analysis showed CHI SQUARE VALUE=45.05 and P value <0.001.

Table 1: Table showing the P16 expression in lesions of the cervix

Category	Number of cases	P16 ^{INK4a} positive	P16 ^{INK4a} negative
Inflammatory	23	01	22
Cin I	05	02	03
Cin II	05	02	03
Cin III	31	26	05
Carcinoma	36	29	07

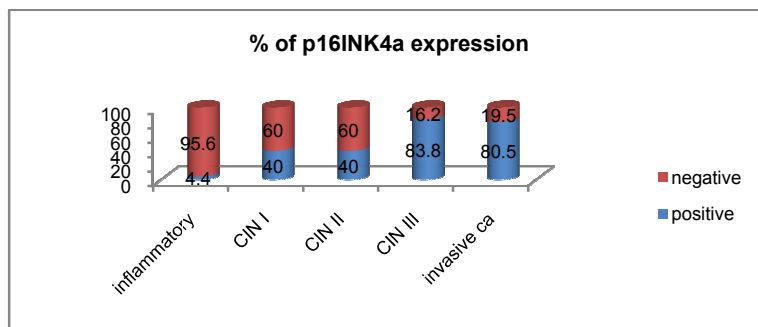


Figure 1: Percentage of P16 expression in cervical lesions

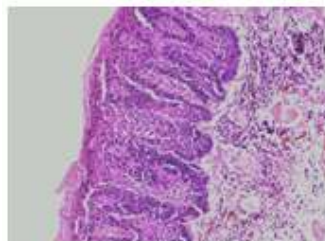


Figure 2: Photomicrograph showing high grade dysplasia-CIN III(H&Ex200)

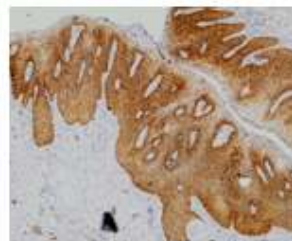


Figure 3: Strong P16 immunostaining in full thickness of the epithelium in CIN III (IHCx200)

DISCUSSION

Human Papilloma Virus (HPV) DNA has been detected in virtually all the cases of cervical dysplasia and carcinoma and is considered to be necessary but not sufficient cause for the development of most invasive squamous cell carcinomas. Most investigators now believe that persistent infection with high risk HR HPV types is associated with the subsequent development of high grade dysplasia. P16INK 4a, a tumor suppressor protein and cyclin dependent kinase (CDK)inhibitor, acts as a tumor suppressor by blocking CDK 4 and CDK 6 mediated pRB phosphorylation resulting in the inhibition of E2F dependent transcription and inhibition of cell cycle progression at the G1 to S check point. Immunohistochemical studies indicate that P16^{INK4a} is highly expressed in virtually 100% of cases of CIN 2, CIN III and SCC, but it is rarely detected in benign squamous mucosa^{10,11} In our study also the staining pattern was negative in 95% cases with chronic cervicitis. In the study by Klaes et al¹⁰ all the inflammatory lesions and lesions with reserve cell hyperplasia were negative for this marker. In their study all the cases of CIN II, CIN III and SCC showed strong diffuse positivity for P16. In our study too, the staining intensity was 2+ to 3+ and diffuse in all the cases of CINIII and SCC. They also noted a sporadic or no staining in CIN I cases. In our study, 2 of the 5 cases of CIN I showed a sporadic or weak positivity. In all our cases if normal epithelia was included in the biopsy, along with the dysplastic areas, the p16 staining was negative. Mulvany et al¹² in their study concluded that the future role of P16^{INK4a} is limited. The ideal diagnostic molecular test for cervical dysplasia will detect a HR HPV related product after, but not before, cell transformation and will reliably predict those cases yet to go for disease progression. In yet another study by Kong et al, focal strong P16^{INK4a} reactivity is less specific, they concluded that cases with this staining pattern are considered atypical and require further evaluation by other means. They felt that P16^{INK4a} IHC is considered the best candidate for the initial assessment of cervical biopsies that are histologically indeterminate for dysplasia, given its wide availability, ease of interpretation and high sensitivity and specificity¹. HPV testing methods and molecular markers like P16^{INK4a} may also help identify cases that are associated with underlying high grade premalignant or malignant lesions and may also reduce aggressive treatment of patients with low grade lesions¹⁴ In a study conducted by Hul¹⁵ on adolescent population, concluded that diffuse full thickness P16^{INK4a} expression discriminated low grade from high grade CIN and appears to be a marker of persistent high risk HPV. Dray et al found a diffuse strong parabasal immunostaining for p16 in the biopsies

which were CINII and CINIII on histology. This was suggestive of a integrated high risk HPV DNA into the host genome. Focal and weak midzonal or superficial p16 immunostaining was suggestive of episomal HPV infection¹⁶. Regarding the staining pattern, Ozgul N et al, found out that the diffuse distribution, full thickness staining pattern and strong intensity of this marker are highly supportive of HSIL and cervical cancer, while focal distribution, scattered/ basal staining pattern and weak intensity suggest LSIL¹⁷ Tissue microarray(TMA) is a well established technology for performing high throughput gene expression analysis in tissue sections. In this technique small cores of formalin fixed paraffin embedded tissues are first removed from a large number of donor paraffin blocks and then arrayed in a new recipient TMA. Iana et al¹⁸ studied the expression of P16^{INK4a} in a large series of 796 cases arranged into TMA format. They also concluded that P16^{INK4a} is a useful diagnostic tool, the expression of which is related is related to the degree of histological dysplasia, suggesting that it may have prognostic or predicative value in the management of cervical neoplasms.

CONCLUSIONS

The use of P16^{INK4a} immunostain is a useful adjunct with H&E stained slides, as it aids to increase diagnostic accuracy and interobserver agreement in the diagnosis of high grade cervical intraepithelial neoplasia and carcinoma.

SOURCE OF SUPPORT

Young Faculty Research grant of Sri Ramachandra University, Chennai

REFERENCES

1. World Health Organisation. Comprehensive cervical cancer control: a guide to essential practice. Geneva, Switzerland: WHO; 2006.
2. Kurman RJ, Henson DE, Herbst AL, Noller KL, Schiffman MH. Interim guidelines for management of abnormal cervical cytology. The 1992 National Cancer Institute Workshop. JAMA 1994;271:1866-9
3. Follen M, Richards-Kortum R. Emerging technologies and cervical cancer. J Natl Cancer Inst. 2000;92:363-5
4. Redman R, Rufforny I, Liu C, Wilkinson EJ, Massoll NA. The utility of P16^{INK4a} in discriminating between cervical intraepithelial neoplasia 1 and non neoplastic equivocal lesions of the cervix. Arch Pathol Lab Med. 2008;132:795-9
5. Sano T, Oyama T, Kashiwabara K, Fukuda T, Nakajima T. Expression status p16 protein is associated with human papilloma virus oncogenic potential in cervical and genital lesions. Am J Pathol. 1998; 153:1741-1748.
6. Tringler B, Gup CJ, Singh M, et al. Evaluation of P16^{INK4a} and Rb expression in cervical squamous and glandular neoplasia. Hum Pathol. 2004; 35:689 – 696.

7. Ismail SM, Colclough AB, Dinner JS, et al. Observer variation in histo pathological diagnosis and grading of cervical intraepithelial neoplasia. *BMJ*. 1989; 298:1030-1031.
8. Abadi MA, Ho GYF, Burk RD, Romney SL, Kadish AS. Stringent criteria for histological diagnosis of Koilocytosis fail to eliminate over diagnosis of human papilloma virus infection and cervical intraepithelial neoplasia grade 1 *Hum Pathol*. 1998; 29:54-59.
9. Klaes R, Benner A, Friedrich T, Ridder R, Herrington S et al. P16^{INK4a} immunohistochemistry improves interobserver agreement in the diagnosis of cervical intraepithelial neoplasia. *Am J Surg Pathol*, 2003 ;27:1284
10. Klaes R, Friedrich T, Spitkovsky D et al. Overexpression of P16 as a specific marker for dysplastic and neoplastic epithelial cells of the cervix uteri. *Int J Cancer* 2001;92:276-284
11. Klaes R, Benner A, Friedrich T et al. P16 immunohistochemistry improves interobserver agreement in the diagnosis of cervical intraepithelial neoplasia. *Am J Surg Pathol*. 2002;26:1389-1399
12. Mulvany NJ, Allen DG, Wilson SM. Diagnostic utility of P16^{INK4a}: a reappraisal of its use in cervical biopsies. *Pathology* 2008;40:335-4414.
13. Kong CS, Blazer BL, Troxell ML, Patterson BK, Longacre TA. P16^{INK4a} immunohistochemistry is superior to HPV in situ hybridisation for the detection of high risk HPV in atypical squamous metaplasia. *Am J Surg pathol* 2007; 31:33-43.
14. Dehn D, Torkko KC, Shroyer KR. Human Papillomavirus testing and molecular markers of cervical dysplasia and carcinoma. *Cancer* 2007;111:1-14.
15. Hul L, Guo M, He Z, Thornton J, Mc Daniel LS, Hughson MD. Human Papillomavirus genotyping and P16^{INK4a} expression in cervical intraepithelial neoplasia of adolescents. *Mod Pathol*. 2005;18:267-73.
16. Dray M, Russell P, Dalrymple C, Wallman N, Angus J, Leong A, Carter J, Cheerla B. P14INK4a as a complementary marker of high grade intraepithelial lesions of the uterine cervix. Experience with squamous lesions in 189 consecutive cervical biopsies. *Pathology* 2005;37:112-24.
17. Ozgul N, Cil AP, Bozdayi G, Usubutan A, Bulbul D, Rota S, Kose MF, Biri A, Haberal A. Staining characteristics of P14INK4a; is there a correlation with lesion grade or high risk human papilloma virus positivity? *J Obstet Gynaecol res*. 2008;34:865-71
18. Iana Lesnikova, Marianna Lidang, Stephen Hamilton Dutoil, Jorn Koch. P16 as a diagnostic marker of cervical neoplasia: a tissue microarray study of 796 archival specimens. *Diagnostic Pathology*. 2009;22 doi;10.1186/1746-1596-4-22.