

A Submucous Intestinal Lipoma Presenting with Intussusception

S. Pani¹, Sujit Prasad², Lisha Suraj³, Vishal Yadav⁴, Gautam Agarwal^{5*}

{¹Professor and Unit Head, ^{2,3}Associate Professor, ⁴Assistant Professor, ⁵Resident}

Department of General Surgery, MGM Hospital, MGM University of Health Sciences, Kamothe, Navi Mumbai, Maharashtra, INDIA.

*Corresponding Address:

g.agarwal@hotmail.com

Case Report

Abstract: Lipomas are common, nonepithelial, benign, fatty tumors that can be found throughout the gastrointestinal tract, although they are most frequently seen in the colon. Approximately 90% of colonic lipomas are located in the submucosa; the remainder of these tumors are subserosal or intramucosal in origin. The reported incidence of colonic lipomas ranges from 0.2% to 4.4%. Lipomas of the large intestine are most commonly seen (in order of decreasing frequency) in the cecum, ascending colon, and sigmoid colon. Of note, more than 70% of these tumors are located in the right hemicolon. Colonic lipomas are more common in women than in men, with a predilection for the right colon in women and the left colon in men. The mean age of patients with colonic lipomas falls within the sixth decade. Colonic lipomas vary in size from several millimeters to 30 cm. Lipomas are usually well-delineated, soft, ovoid, yellowish masses. These tumors can be found by themselves or in groups, and they can be sessile or pedunculated. Several cases of primary colonic liposarcomas have been reported in the literature, whereas other lipomas are mostly seen in conjunction with retro-peritoneal liposarcomas.

Keywords: Submucous Intestinal Lipoma, Intussusception.

Introduction

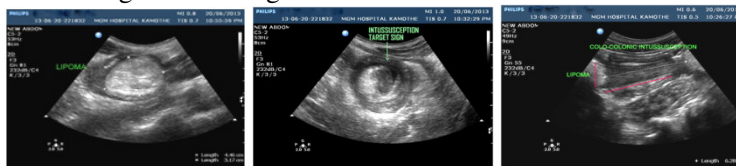
Colonic lipomas are generally asymptomatic and are found incidentally during a colonoscopy or surgery for other conditions. Symptoms correlate with the size of the lipoma; lipomas larger than 4 cm in size become symptomatic in 75% of patients.^{5,6} Lipomas often present with vague symptoms—such as abdominal pain and/or alterations in bowel habits—and rarely manifest as gastrointestinal bleeding, perforation, or obstruction.⁷ Giant lipomas (>4 cm) are the most common benign tumors in the colon that cause intussusception, although no specific incidence data have been documented.⁸ Even patients with large lipomas may have nonspecific or intermittent symptoms, which causes delay and difficulty in making the diagnosis.

Intussusceptions are usually limited to 1 segment of the colon—either ascending, transverse, or descending—but can extend to more than 1 segment in some cases.⁹ Large lipomas may develop superficial ulceration and bleeding and may present with a combination of symptoms.¹⁰ Due to similarities in age and symptoms, colonic lipomas may mimic malignancy in presentation.

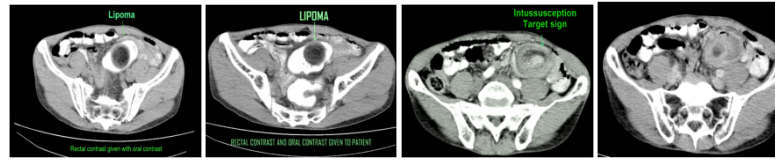
Case

Intestinal Lipoma presenting with Intussusception

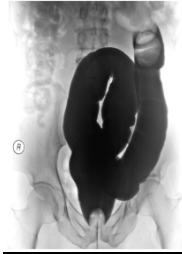A 65 year male came with chief complaints of intermittent bleeding per rectum since 2 weeks and abdominal pain since 2 weeks. Pain generalized all over the abdomen, cramping nature, intermittent, aggravated after consumption of food, non radiating, non referred. No history of any associated medical / surgical history. **General examination:** Moderately built and nourished, well oriented in time, place and person, comfortable in supine position. Afebrile Pulse - 76/min. B.P - 120/80 mm hg. No signs of pallor, icterus, cyanosis, clubbing, lymphadenopathy or edema feet. **Systemic Examination:** R.S - AEBE, Clear, no adventitious sounds heard. C.V.S - S1 S2 normal. C.N.S - conscious, oriented. Per Abdominal Examination: Palpable lump in the left lumbar region, 5*8*5 cms which was non tender with limited mobility. No guarding, rigidity. No organomegaly. Rectal examination showed blood stained fecal matter. **Investigations:** Complete haematological assessment - NAD. USG abdomen suggestive of sluggish peristalsis noted in descending colon with mass visualized approx 5*5*6 cms in descending colon. A CT abdomen was done which showed features suggestive of Intussusception in the descending colon.



Ultrasonography



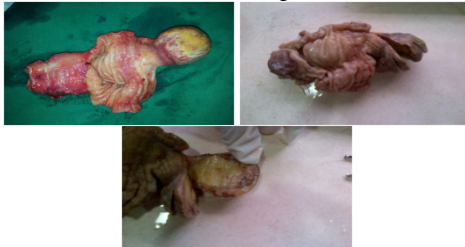CECT Scan Abdomen and Pelvis



Barium Enema

Treatment

- He underwent a Laparotomy which showed a 4*3 * 3 cm mass in the descending colon and a Resection Anastomosis was done in the descending colon.
- Histopathology report was suggestive of an Intestinal submucosal Lipoma.



Discussion

The presence of intussusception, irregular margins, lymph node enlargement, or thickening of the bowel wall—in association with a mass seen on imaging—raises suspicion for a malignant etiology.¹¹ Similarly, colonoscopic findings—such as the presence of a firm or fungating mass, ulceration, or necrosis—are concerning for malignancy.¹² Even experienced endoscopists may mistake a large colonic lipoma for a large polyp or colorectal cancer. Surgical resection is the treatment of choice when giant lipomas are complicated by intussusception or bowel obstruction. Surgical resection should also be the first-line management for lipomas that are sessile, have limited peduncles, or have extension of serosa/muscularis propria into the pedicle. When attempted endoscopic resection fails, large lipomas should be removed surgically. Various surgical techniques—such as hemicolectomy, segmental resection of the involved colon, or local excision—have all been

used with success. However, local excision should be considered whenever feasible in order to limit morbidity.

Outcome

Both surgical and endoscopic resection of colonic lipomas show good outcomes with no known recurrence after complete removal. The key take-home message should be that while most colonic lipomas are small and asymptomatic, larger lesions may mimic polyps or tumors, cause a variety of symptoms, and warrant surgery.

References

1. Vecchio R, Ferrara M, Mosca F, Ignoto A, Latteri F. Lipomas of the large bowel. *Eur J Surg.* 1996;162:915–919.
2. Zhang H, Cong JC, Chen CS, Qiao L, Liu EQ. Submucous colon lipoma: a case report and review of the literature. *World J Gastroenterol.* 2005;11:3167–3169.
3. Bardaji M, Roset F, Camps R, Sant F, Fernández-Layos MJ. Symptomatic colonic lipoma: differential diagnosis of large bowel tumors. *Int J Colorectal Dis.* 1998;13:1–2.
4. Choi YY, Kim YJ, Jin SY. Primary liposarcoma of the ascending colon: a rare case of mixed type presenting as hemoperitoneum combined with other type of retroperitoneal liposarcoma. *BMC Cancer.* 2010;10:239.
5. Roky MA, Mirza D, Berlakovich G, Winkelbauer F, Rauhs R. Submucous large-bowel lipomas—presentation and management. An 18-year study. *Eur J Surg.* 1991;157:51–55.
6. Bahadursingh AM, Robbins PL, Longo WE. Giant submucosal sigmoid colon lipoma. *Am J Surg.* 2003;186:81–82.
7. Castro EB, Stearns MW. Lipoma of the large intestine: a review of 45 cases. *Dis Colon Rectum.* 1972;15:441–444.
8. Gordon RT, Beal JM. Lipoma of the colon. *Arch Surg.* 1978;113:897–899.
9. Paskauskas S, Latkauskas T, Valeikaitė G, *et al.* Colonic intussusception caused by colonic lipoma: a case report. *Medicina (Kaunas)* 2010;46:477–481.
10. Gould DJ, Morrison CA, Liscum KR, Silberfein EJ. A lipoma of the transverse colon causing intermittent obstruction: a rare cause for surgical intervention. *Gastroenterol Hepatol (NY)* 2011;7:487–490.
11. Zhang X, Ouyang J, Kim YD. Large ulcerated cecal lipoma mimicking malignancy. *World J Gastrointest Oncol.* 2010;2:304–306.
12. Martin P, Sklow B, Adler DG. Large colonic lipoma mimicking colon cancer and causing colonic intussusception. *Dig Dis Sci.* 2008;53:2826–2827.