

Basal Cell Adenoma of Parotid Gland

Yarlagadda Subba Rayudu¹, Sharmila Dhulipalla^{2*}

{¹Associate Professor, ²Assistant Professor}

Department of ENT, ASRAM Medical College and Hospital, AP-522001, INDIA.

Corresponding Addresses:

¹ysrayudu@yahoo.com, ²dhulipallasharmila@yahoo.com

Case Report

Abstract: Basal cell adenoma of the salivary glands is an uncommon type of monomorphous adenoma. Its most frequent location is the superficial lobe of parotid gland. It usually appears as a firm and mobile slow-growing mass. In contrast to pleomorphic adenoma, it tends to be multiple and its recurrence rate after surgical excision is high. We describe a case of basal cell adenoma of the parotid gland.

Keywords: Basal cell adenoma, parotid, salivary gland.

Introduction

Basal cell adenoma (BCA) of the salivary glands is a rare tumour, recognized as an independent entity in the Second Edition of the Salivary Gland Tumours Classification of the World Health Organization (WHO) [1]. It is considered as a low-grade malignant tumour with a high recurrence rate and, in general, good prognosis. The most frequent location is the parotid gland, although other sites are possible, such as the upper lip, buccal mucosa, lower lip, palate and nasal septum[2,3]. It represents 54% of monomorphous adenomas and 1-3% of major salivary glands tumours[4]. Epidemiologically, these tumours frequently affect patients between their fifth and seventh decades. In the opinion of most authors prevalence in favour of women exists, but other authors report a similar frequency for both genders [5, 6].

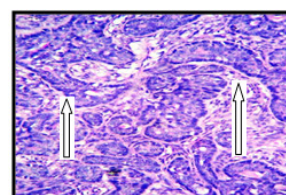
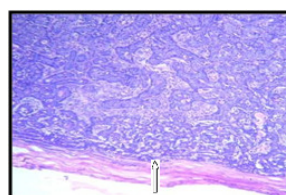
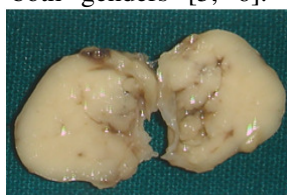
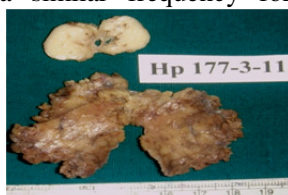

Figure 1: Below: C/S Superficial Lobe. **Figure 2:** C/S of the lesion, gray white, homogenous, capsulated showing Capsulated Tumour. **Figure 3:** X10(Low Power view) H and E Stained Section showing tumour cells arranged in characteristic basaloid pattern i.e. peripheral palisading of tumour cells. **Figure 4:** X40(High Power view) H and E Stained Section showing tumour cells arranged in characteristic basaloid pattern i.e. peripheral palisading of tumour cells.

In the histological study an 18-mm white-coloured homogeneous and well-defined tumour was observed in the deep lobe of the parotid gland [Fig-1, 2]. In the microscopic study, an encapsulated lesion was observed [Fig-3]. It was formed by trabecules or nests separated by an eosinophilic basal membrane, and basaloid cells disposed in a peripheric stockade pattern [Fig-4]. The

Histologically, 4 characteristic patterns have been described: solid, trabecular, tubular and membranous. It is characterized by the presence of a basaloid cellular layer with a stockade pattern and rounded by hyaline substance [7].

Case Report

A 53-year old female patient by name Rajyalakshmi came to our hospital with history of slow-growing swelling in the region of the right mandibular angle since 3yrs. The patient had a previous pathological report performed in other centre consisting of two fine-needle aspiration (FNA) procedures, with result suggestive of low-cytological grade epithelial proliferation. Due to its slow progression in 3 years, it was interpreted as a benign tumoral lesion, such as pleomorphic adenoma, Warthin tumour and other benign lesion. With clinical and pathological diagnosis of benign tumour of the right parotid gland, a total parotidectomy under general anesthesia was performed. A well demarcated mass is seen in deep lobe of right parotid gland. No important complications during the immediate postsurgical period were observed.

histological study was basal cell adenoma of parotid gland.

Discussion

Most of parotid tumours (70-80%) are benign and, within this group, pleomorphic adenoma is the most frequent. Within the adenomas group, monomorphic tumours are very uncommon. They are defined as epithelial benign

tumours of the salivary glands which are not pleomorphic adenomas. Within this group, basal cell adenoma must be signalled. This tumour is subdivided into solid, trabecular, tubular and membranous subtypes. It is a firm mobile painless mass. It is usually superficial within the glandular body. The diagnosis of this entity must be established by the histological study. Generally, biopsy is accepted as the most accurate method to obtain the diagnosis, although some authors advocate for FNA if physical access to the tumour is available. Our case presented histological features similar to those referred in the literature, consisting in basaloid cells disposed in an external stockade pattern and pale-nuclei cells in the centre of the nests. Differential diagnosis must be mostly established with some unfavourable entities, such as the basal cell adenocarcinoma, adenoid cystic carcinoma and basaloid squamous cell carcinoma. In contrast to BCA, an infiltrative growth, more mitotic figures (>4 mitotic count/10 HPF) and Ki67-staining of 5% of the cells are observed in basal cell carcinoma [8]. It is interesting that BCA have macroscopic features that may help in the differential diagnosis. Tumoral nests are clearly differenced from inter-epithelial stroma because of an intact basal-cell membrane. This delimitation is observed neither in the pleomorphic adenoma nor in the adenoid cystic carcinoma. In addition to the histological diagnosis, immunohistochemical analysis is of great help in confirmation of diagnosis. Primary treatment of BCA is surgical excision by means of a suprafacial or total parotidectomy. Total parotidectomy rather than suprafacial parotidectomy has been proposed in the membranous type of BCA. It is due to the elevated tendency to multicentricity, multiple recurrences and occasional malignant transformation [9]. It is mandatory not to disrupt the capsule, in order to minimize the risk of recurrence which is observed in rare occasions. Malignization of this tumour has been referred in two occasions [3]. Despite this benign behaviour, we think

that it is completely necessary for long-term follow-up, in order to detect recurrences in a prompt time.

Conclusion

Basal cell adenoma is a very rare benign parotid tumor. Complete surgical excision is the treatment of choice. Confirmatory diagnosis can be made by histopathological examination.

References

1. Seifert G, Sobin LH. The World Health Organization's Histological Classification of Salivary Gland Tumors. *Cancer* 1992; 70:379-85.
2. Mintz GA, Abrams AM, Melrose RJ. Monomorphic adenomas of the major and minor salivary glands. Report of twenty-one cases and review of the literature. *Oral Surg* 1982; 53:375-86.
3. Bernacki EG, Batsakis JG, Johns ME. Basal cell adenoma. Distinctive tumor of salivary glands. *Arch Otolaryngol* 1974; 99:84-8.
4. Luna MA, Tortoledo ME, Allen M. Salivary terminal analogue tumors arising in lymph nodes. *Cancer* 1987; 59:212-24.
5. Chaudhry AP, Cutler LS, Satchidanand S, labay G, Sunderraj M. Ultrastructure of monomorphic adenoma (ductal type) of the minor salivary glands. *Arch Otolaryngol* 1983; 109:118-22.
6. Fantasia JE, Neville BW. Basal cell adenomas of the minor salivary glands. A clinicopathologic study of seventeen new cases and review of the literature. *Oral Surg* 1980; 50:433-40.
7. Nagao K, Matsuzaki O, Saiga H, Sugano I, Shigematsu H, Kaneko T, *et al.* Histopathologic studies of basal cell adenoma of the parotid gland. *Cancer* 1982; 50:736-45.
8. Nagao T, Sugano I, Ishida Y, Hasegawa M, Matsuzaki O, Konno A, *et al.* Basal cell adenocarcinoma of the salivary glands: comparison with basal cell adenoma through assesment of cell proliferation, apoptosis, and expression of p53 and bcl-2. *Cancer* 1998; 82:439-47.
9. Yu GY, Ubmüller J, Donath K. Membranous basal cell adenoma of the salivary gland: a clinicopathologic study of 12 cases. *Acta Otolaryngol (Stockh)* 1998; 118:588-93.