

Rare case of Congenital Anomaly of the Kidney with Stone Disease: A Case Report

Deepak Bolbandi^{1*}, Shubhatara Swamy², Nayanatara³

¹Assistant Professor Department of Urology, Rajarajeshwari Medical College, Bangalore, Karnataka, INDIA.

²Clinical Research Assistant, ³Consultant Radiologist

*Corresponding Address:

deepakbolbandi@gmail.com

Case Report

Abstract: If a kidney does not ascend as it should in normal foetal development it remains in the pelvic area and is called a pancake kidney. Often a person with a pancake kidney will go through their whole life not even knowing they have this condition, unless it is discovered on newborn kidney ultrasound screening or if complications arise later in life for this or a completely different reason, and during investigations the condition is diagnosed. It is not a harmful condition generally, but can develop complications. Here we present an rare and interesting case of Pancake kidney with renal calculi.

Keywords: pancake kidney, congenital anomaly, renal calculi, PCNL, flexible cystoscopy, holmium laser.

Case

46 year old male patient presented with pain abdomen since one year. Pain increased with urination and had history of dysuria and fever 6 months back. He was managed conservatively for the same. Abdominal examination revealed palpable mass in the umbilical region and tenderness in the left iliac fossa. Ultrasound was performed which showed the presence of 16X13mm Renal calculi in the fused kidney. CT scan plain and contrast was performed showed 15X12mm calculi in the pan cake kidney with dilatation of the pelvicalyceal system. The upper pole of the kidneys was fused (figure 1, 2). There was dilatation of the left pelvicalyceal system and stone in the pelviureteric junction.

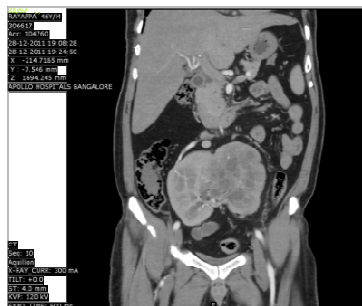

Figure 1: CT scan showing pancake kidney

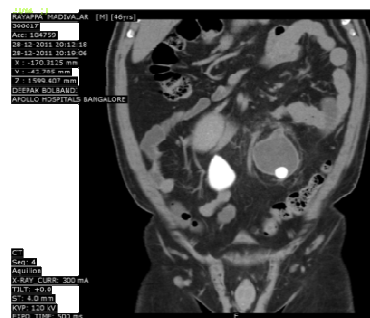


Figure 2: CT scan showing left renal calculus

The patient underwent PCNL under general anaesthesia. The puncture was done using combined ultrasound and C-Arm guidance. The difficulty was encountered in the manoeuvring the Nephroscope and the Amplatz sheath in the collecting system. However as the stone was in the pelvis 100% stone clearance was achieved.

Discussion

Pancake kidney (also known as discoid kidney or doughnut kidney or disc kidney) is a rare renal fusion anomaly of the kidneys of the crossed fused variety [1]. It is characterised by a displaced, lobulated pelvic renal mass of dual parenchymatous system without any intervening septum [1]. The upper and lower poles of the kidneys are fused hence giving it an appearance of pancake. Anomalies of position and fusion include kidneys that have migrated to become fused with the contra lateral mate and are subdivided clinically on the basis of whether both or only one kidney moves toward or crosses the midline[2]. Pancake kidneys are prone to cause stasis of urine, pyelectasis, caliectasis, infection, and stone formation. The anomalous position of the kidneys, pelvis, and ureter predisposes to poor drainage and may result in extensive hydronephrosis [3]. Management of renal stones in pancake kidney requires advanced urology set up in the form of ultrasound guided puncture arm guided dilatation of the tract. The main difficulty is noted if there is partial stag horn or complete

stag horn calculi. The flexible nephroscope and holmium laser standby is mandatory as the rigid nephroscope cannot be easily manoeuvred and hence flexible nephroscope is required in some cases.

References

1. Eze AR, White JV, Pathak AS et-al. "Pancake kidney": a renal anomaly Ann Vasc Surg. 1998; 12 (3): 278-81.
2. McDonald HJ, McClellan DS. Crossed renal ectopia. Am J Surg. 1957; 93: 995-998.
3. Dyer RB, Chen MY, Zagoria RJ. Classic signs in urology. Radiographics. 2004; 24 Suppl 1 (suppl 1): S247-80.