Research Article

Musculus sternalis: a mystery muscle

Vaibhav Vasudevrao Phad[1*], S. A. Syed[2], R. A. Joshi[3], N. G. Herekar[4]

[1]Assistant Professor, [2]Assistant Professor, [4]Professor and HOD, Department of Anatomy, Government Medical College, Miraj, District Sangli 416410, Maharashtra, INDIA.
[3]Professor and HOD, Department of Anatomy, RCSM Government Medical College, Kolhapur, Maharashtra, INDIA.
Email: drvaibhavphad@gmail.com

Abstract

Introduction: Rectus column gives rise to various muscles extending from pubic symphysis to symphysis menti. These are well developed in neck region represented by supra-hyoid and infra-hyoid muscles, in abdominal region represented by rectus abdominis. In thorax this layer usually disappears but occasionally remains as musculus sternalis. During study we dissected 12 cadavers and encountered a musculus sternalis on right side of 60-year-old male cadaver covered by superficial fascia and located anterior to the pectoralis major muscle. Knowledge regarding the muscular variations of the anterior wall of chest and their identification is important for radiological examinations such as mammography. The existence of the musculus sternalis should not be overlooked in the surgical and diagnostic procedures.
Keywords: Pubic symphysis, symphysis menti, supra-hyoid, musculus sternalis.

***Address for Correspondence:**
Dr Vaibhav Vasudevrao Phad, Assistant Professor, Department of Anatomy, Government Medical College, Miraj- 416410 Dist Sangali, Maharashtra, INDIA.
Email: drvaibhavphad@gmail.com
Received Date: 14/07/2014 Accepted Date: 28/07/2014

Access this article online	
Quick Response Code:	Website: www.statperson.com
	DOI: 02 August 2014

INTRODUCTION

The Musculus Sternalis is an uncommon anatomic variation of chest wall musculature. The muscle is described as thin, flat and long arising from the anterior chest wall, below the clavicle, running parallel to the sternum but superficial to the medial part of the rectus abdominis muscle, and finally gaining insertion into the costal cartilages, the lower end of the sternum or the external oblique aponeurosis of the abdomen.[1] This seems to be simple and short explanation about this muscle. But then from its first mention by Cabrolius in 1604 it has provided a wealth of uncertainty and debate.[2] The sternalis has undergone examination after examination with regard to such vital considerations as its origin, nerve supply, function, ethnic prevalence, and clinical significance. It has been called by various authors as *musculus sternalis, presternalis, rectus sternalis, sternalis brutorum, or thoracicus, sternalis, the episternalis, the rectus thoracis, the superficial rectus abdominis..... and so many names.*[3] During the dissection of 12 cadavers we have found presence of one unilateral musculus sternalis.

INCIDENCE

In present study the incidence appears to be 8.33%. The incidence varies in racial and ethnic groups within the range of 3% to 6%, irrespective of sex, races of European descent show (4.4%), people of African descent (8.4%), and the greatest incidence was seen in Asian populations (11.5%).[3]

MATERIAL AND METHODS

Study is carried on embalmed cadavers in our dept. used for routine dissection. In the year 2012- 2013, we have done the dissection of 12 bodies, and found presence of a single unilateral musculus sternalis sheet extending from lower end of sternocleidomastoid to aponeurosis of external oblique muscle as shown in (figure 1). Its origin, insertion, nerve supply, length, width noted in detail.

RESULTS

One male cadaver out of 12 embalmed human cadavers over a period of 1 year was observed to exhibit unilateral musculus sternalis. Muscle mass was located on the

How to site this article: Vaibhav Vasudevrao Phad, S. A. Syed, R. A. Joshi, N. G. Herekar. Musculus sternalis: a mystery muscle. *International Journal of Recent Trends in Science and Technology* August 2014; 12(1): 60-62 http://www.statperson.com (accessed 04 August 2014)

anterior chest wall, in a paramedian position, deep to the skin and superficial fascia of the pectoral region, but superficial to the pectoral fascia and the pectoralis major muscle. It was 11.3 cm long and 2.3 cm broad as shown in (figure 2). It was attached to right part of the front of manubrium sterni and sternal tendon of right sternocleidomastoid muscle, descended vertically to gain lower attachment to the right 5th and 6th costal cartilages and the aponeurosis of right external oblique muscle of the abdomen taking part in the formation of the anterior wall of the right rectus sheath (figure 1). Nerve supply of the rectus muscle was found to be from the anterior cutaneous branches of right 3rd and 4th intercostal nerves (figure 3). The pectoralis major muscle, on each side, was morphologically normal without presenting any anomaly or variation.

Figure 1: Showing Musculus sternalis muscle present on right side attachment extending from sternocleidomastoid to external oblique aponeurosis pectoralis major cut down on both sides

Figure 2: Showing measurement of musculus sternalis muscle 11.3 cm long and 2.3 cm broad

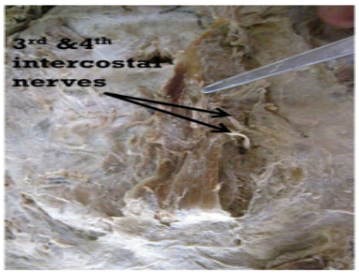

Figure 3: Showing nerve supply of musculus sternalis muscle supplied by 3rd and 4th intercostals nerves through anterior perforating branches

DISCUSSION

Although muculus sternalis was first described 3 centuries ago (1604), its origin is still doubtful. It is assumed that this muscle is developed from one or more of the neighbouring muscles such as the ***pectoralis major muscle, the sternocleidomastoid muscle, the rectus abdominis muscle, external oblique muscle, or as a remnant of panniculus carnosus.***[3] To know the exact origin of this muscle, let us discuss development and origin of any muscle. Myotome portion of the somites gives rise to most of the skeletal muscles of the body. Shinohara[4] reported three laws (migration, fusion and separation) on nerve-muscle specificity for understanding origin of any muscle. The law of migration, the nerve is regarded as an indicator of the route along which the muscle mass is originated and migrated (i.e. diaphragm). In the law of fusion, when a muscle is supplied by two different nerves, such muscle is considered to be formed by fusion of two muscle masses, each of which was originally supplied by a separate nerve. Some muscle, e.g. the external oblique, are supplied both from the superficial and deep surfaces, and this dual surface supply is interpreted as suggesting that the muscle is a composite muscle. According to the law of separation, two different muscles supplied by a single nerve are considered to be derived from a single muscle mass (i.e. common muscle mass for the sternocleidomastoid and trapezius muscles).[4] On the basis of all these laws musculus sternalis had been considered to be a part of

A. *Pectoralis major* as in many studies its nerve supply comes from branches of lateral (external) and medial pectoral nerves (internal anterior thoracic) supplying to pectoralis major. (For e.g. Shepherd in 7, Wallace in 1, Lamont in 6, Dwight in 2, Cunningham in17, O'Neill, Folan-Curran 55% cases).[5] O'Neill and Folan-Curran reported the direct connection of muscle fibers between the sternalis and pectoralis major muscle.[6] Additionally, Kida *et al*. reported the partial absence of sternocostal portion of the pectoralis major muscle.[7] When the sternalis muscle is associated partial or complete congenital absence of the pectoralis major muscle, it may achieve significant size. Hallett's 1848 quoted when fully developed it (i.e., musculus sternalis) can act as an elevator of the ribs.[6]
B. *Rectus abdominis, External oblique aponeurosis, and sternocleidomastoid* M. Testut expresses his belief that the musculus sternalis in its upper part belongs to the sternomastoid, whilst in its lower part it belongs to the external oblique. He points out that these two muscles in serpents they are continuous, as Professor Humphry has shown so conclusively, that anterior fasciculi of the external oblique in the

serpent represent the sternomastoid in the bird, and mammal.[1] Nerve supply of this muscle comes from intercostal nerves also found by many others.[8] (Hallett in1, Bardeleben in 2, Dwight in 2, O'Neill and Folan-Curran in 43% cases, Sadler in langmans medical embryology agrees with this view.)[6] In our case as well as many recent studies the nerve supply was from intercostal nerves. Both these views appear to be valid.

C. *Panniculus carnosus* (Turner, Ruge, Barlow) view is no longer valid, as it lies in deeper plane than platysma.[6] But these views were not satisfying following queries:
   1. In 2% cases of O'Neill, it was supplied by both anterior thoracic and intercostal nerves as also seen in some other cases.
   2. It lies in superficial plane than pectoralis major, external oblique and sternocleidomastoid muscles. All these muscles together represent the external oblique of the serpents and derivative of ventral longitudinal column in humans.
   3. According to Bergman *et al*., this muscle is present in humans only, and not seen in other animals.

Kida *et al*. suggest that it is difficult to find the twigs from the pectoral nerves supplying the sternalis muscle because when the lateral rim of the sternalis muscle has been clearly dissected, the very fine twigs, easily confused with the connective tissue, are almost always removed or damaged.[7] When all these points were taken into consideration one can say that sternalis is derived is derived from ventral longitudinal column, as a reversion of pectoral fibres of pectoralis major (Cunningham), and also partly from anterior fasciculus of external oblique deriving its nerve supply from both sources.[1] Its occurrence in man was attributed to adoption of erect posture. The most rational view is to consider the variation as a reversion, (not as a rudimentary muscle) which, when occurs, performs a useful function, and may therefore in time become firmly established as a normal condition.

CONCLUSION

During routine mammography, sternalis muscle may be visible medially on the craniocaudal projection, as a density with an ill-defined margin and can give rise to diagnostic confusion with a breast cancer, can present alterations on the ECG.[9] Occasionally be wrongly interpreted as a mass requiring surgical resection.[10] Sternalis may interfere with submuscular pocket dissection when an intraalveolar or submammary approach is used.[10] It can be used to cover the prosthesis in its most medial part and can be used for reconstruction surgery after mastectomy.[10]

REFERENCES

1. D. J. Cunningham, M.D The musculus sternalis.. (Edin. and Dubl.), Professor of Anatomy and Chirurgery in the University of Dublin. Journal of anatomy and physiology 1888
2. Turner WM. On the musculus sternalis. J Anat Physiol 1867; 1:246-53.
3. Marios Loukas, Maggi Bowers, Joel Hullett. Sternalis muscle: a mystery still Folia Morphol. 2004. Vol. 63, No. 2, pp. 147–149.
4. Shinohara H. A. Warning against revival of the classic tenets of gross anatomy related to nerve-muscle specificity. J Anat 1996; 188 (Pt 1): 247-8.
5. Bergman RA, Thompson SA, Afifi AK, Saadeh FA. Compendium of Human Anatomic Variation. Baltimore: Urban and Schwarzenberg; 1988.
6. O'Neill MN, Folan-Curran J.Case report: bilateral sternalis muscles with a bilateral pectoralis major anomaly. J Anat 1998; 193 (Pt 2): 289-92.
7. Kida MY, Kudoh H. Innervation of the sternalis muscle accompanied by congenital partial absence of the pectoralis major muscle. Okajimas Folia Anat Jpn 1991; 67: 449-55.
8. Sadler TW. Langman Medical Embryology. 7th ed. Baltimore: Williams and Wilkins; 1995. 25.
9. Bradley FM, Hoover HC, Jr., Hulka CA, *et al*. The sternalis muscle: an unusual normal finding seen on mammography. AJR Am J Roentgenol 1996; 166: 33-6.
10. Bailey PM, Tzarnas CD. The sternalis muscle: a normal finding encountered during breast surgery. Plast Reconstr Surg 1999; 103: 1189-90.

Source of Support: None Declared
Conflict of Interest: None Declared