Case Report

A rare cause of intestinal obstruction: ileal squamous cell carcinoma - a case report

Debasish Bhattacharya[1*], Subhadip Khatua[2], Abhijit Banerjee[3]

[1]Assistant Professor, [2,3]PG, Department of Pathology, Burdwan Medical College, Burdwan, West Bengal, INDIA.
Email: neelsayan@yahoo.co.in

Abstract

Introduction: Small bowel obstruction caused by metastatic lesion from other primary cancer is a rare event. The most common types of tumor metastasizing to the small bowel are malignant melanoma, carcinoma from lung, breast, and ovary, and choriocarcinoma Idelevich ***et al.*** reviewed the literature and found that between 1988 and 2005, only 36 cases have been reported. Interestingly, the most common primary cancer in these cases was lobular breast carcinoma (47%), followed by lung cancer (11%) and malignant melanoma (8%), most of which are adenocarcinoma.. Rarely however, does it selectively affect the small bowel in the form of an isolated metastatic stricture. We are reporting such a case of **terminal ileum obstruction due to metastatic deposit of invasive** cervical **squamous cell carcinoma**, 8 months after total abdominal hysterectomy, emphasizing role of meticulous searching of lymph nodes during surgery of cervical carcinoma to avoid such fatal complication.

Keywords: Squamous cell carcinoma, Ileum, Obstruction.

***Address for Correspondence:**
Dr. Debasish Bhattacharya, Department of Pathology, Burdwan Medical College, Burdwan, West Bengal, INDIA.
Email: neelsayan@yahoo.co.in
Received Date: 20/11/2014 Accepted Date: 01/12/2014

Access this article online

Website: www.statperson.com

DOI: 02 December 2014

INTRODUCTION

Small bowel obstruction caused by metastatic lesion from other primary cancer is a rare event[4]. The most common types of tumor metastasizing to the small bowel are malignant melanoma[1]. Idelevich *et al.* reviewed the literature and found that between 1988 and 2005; only 36 cases have been reported[2]. Interestingly, the most common primary cancer in these cases was lobular breast carcinoma (47%), followed by lung cancer (11%) and malignant melanoma (8%), most of which are adenocarcinoma. Rarely however, it selectively affect the small bowel in the form of an isolated metastatic stricture. We are reporting such a case of a metastatic stricture of the terminal ileum originating from cervical carcinoma which is squamous cell carcinoma in nature.

CASE REPORT

43 year old female presented with symptoms of chronic intestinal obstruction for last 3 months with a past history of invasive cervical carcinoma for which she had undergone total abdominal hysterectomy 8 months back. On admission she was severely dehydrated with tachycardia absent bowel sound and electrolyte disbalance. Patient was planned for immediate surgery. On exploration, she was found to have an impassable single stricture in the terminal ileum. The bowel proximal to the stricture was dilated. Mesentric lymph nodes found to be enlarged adjacent to that. There was no evidence of visceral metastasis, peritoneal seedlings or ascites. A right hemicolectomy was performed and received in our department along with enlarged mesenteric lymph nodes. Grossly, there was a hard mass (2cm X 3cm) just proximal to ileocaecal junction almost impassable, causing a single stricture in ieum, with dilatation of lumen proximal to that with Ileal wall thinning and blackish staining, along with attached enlarged mesenteric lymph node (figure: 1). On histopathological evaluation it is evident that mucosal folds are normal with normal glandular configuration, but submucosal area shows pleomorphic malignant squamous cells in sheets and clusters with abundant eosinophilic cytoplasm.(figure:2) Mitotic count was high in the clusters of tumor cells. There was metastatic deposit of squamous cell carcinoma in mesenteric lymph lodes and vascular invasion evident at places(figure 3A and 3B) favouring possibility of hematogenous and lymphatic spread of tumor.

How to site this article: Debasish Bhattacharya, Subhadip Khatua, Abhijit Banerjee. A rare cause of intestinal obstruction: ileal squamous cell carcinoma - a case report. *International Journal of Recent Trends in Science and Technology* December 2014; 13(2): 260-261 http://www.statperson.com (accessed 02 December 2014).

Figure 1: Gross specimen of resected specimen showing stricture causing mass, dilated terminal ileum with blackish discoloration of mucosa and enlarged mesenteric lymph node

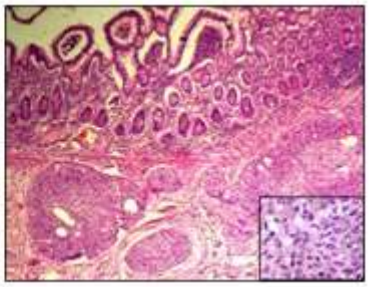

Figure 2: Microphotograph showing normal mucosa of terminal ileum with intact muscularis mucosa and presence of malignant squamous cells in clusters Inset: Malignant cells under higher magnification

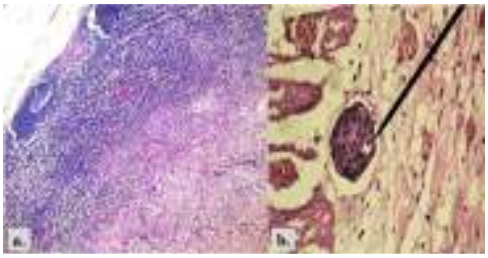

Figure 3: a: Involvement of mesenteric lymph node by metastatic squamous cell carcinoma
b: Presence of lymphovascular invasion in the wall of terminal ileum

DISCUSSION

Secondary involvement of the small intestine in the malignant disease is rare and seen almost always as a part of the generalized spread with multiple seedlings in the peritoneal cavity and frequently with ascites[4]. Rarely, the secondary tumor of the ileum may be a solitary nodule. DeCastro *et al*[3], in 1957, reported 26 cases of solitary metastatic nodules of the small bowel. Farmer and Hawk[6] found only 14 cases of discrete lesions of the small bowel in a series of 87 metastatic carcinoma patients. Idelevich *et al*[2]. reviewed the literature and found that between 1988 and 2005, only 36 such cases have been reported. Interestingly, the most common three primary cancer in these cases was lobular breast carcinoma (47%), followed by lung cancer patient may present with perforation of the bowel or hemorrhage from the lesion. Diagnosis of intestinal obstruction due to a metastasis should be suspected if, in addition, there are symptoms pertaining to a primary lesion or if the patient gives a history of having received treatment for a primary malignancy in the past. Treatment is essentially in the form of either a palliative intestinal resection or a bypass surgery to relieve intestinal obstruction as done in the present case.

CONCLUSION

Though rare, it is necessary to keep in consideration that cervical carcinoma may metastasize to small intestine through retrograde lymph node spreading, peritoneal seeding, as observed in this case. For this meticulous search of lymph nodes is needed during surgery and depending on that, post operative chemotherapy or radiotherapy should be considered to prevent future fatal complications.

REFERENCES

1. Adair C, Ro JY, Sahin AA, El-Naggar AK, Ordóñez NG, Ayala AG: Malignant melanoma metastatic to gastrointestinal tract. A clinicopathologic study. *Int J Surg Pathol* 1994; 2:3-10.
2. Idelevich E, Kashtan H, Mavor E, Brenner B. Small bowel obstruction caused by secondary tumors. Surg Oncol 2006:15:29-32 [PubMed]
3. DeCastro, C. A., Dockerty, M. B. and Mayo, C. w.: Metastatic tumours of the small intestine. Surg. Gynaecol. and Obstet., 105: 159-165, 1957
4. Howley, P. R. and Morson, B. C.: Tumours of the small intestine. In, "Abdominal Operations." Editors: R.. Maingot, 7th Edition. Appleton-Century Crofts, New York, 1980, pp.1972.
5. Hendrikson, E.: Quoted by Bradley Watson, P. J. and Leiman, G.: Ileal metastasis in cervical carcinoma. A case report. South Afr. Med. J., 50: 1937-1938, 1976
6. Farmer, R. G. and Hawk, W. A.: Metastatic tumours of the small bowel. Gastroenterology, 47:496-504, 1964.

Source of Support: None Declared
Conflict of Interest: None Declared