

Usefulness of dexmedetomidine as an adjuvant to local anaesthetics in infraclavicular brachial plexus block for prolongation of postoperative analgesia

Prashant Lomate^{1*}, Divakar Patil², Vasudha Jadhav³, Trupti Deshpande⁴, Manisha Patil⁵

¹Assistant Professor, ²Professor & HOD, ³Professor, ^{4,5}Senior Resident, Department of Anaesthesia, Bharati Vidyapeeth Deemed University Medical College and Hospital, Sangli, Maharashtra, INDIA.

Email: drprashantlomate@gmail.com

Abstract

Background and Objectives: The infraclavicular brachial plexus block is a safe and reliable approach to provide intraoperative and postoperative analgesia of upper limb. We evaluated the efficacy of dexmedetomidine added to local anaesthetics in infraclavicular brachial plexus block to hasten the onset of sensory and motor block and to prolong the postoperative analgesia. **Methods:** A prospective randomized double-blind study was carried out in 60 patients aged 18-60 years of ASA grade I and II, who were scheduled for various upper limb surgeries in orthopedics. The patients were divided into two groups of 30 each i.e. **Control Group** (group C) received 20 ml of inj. Bupivacaine + 10 ml of inj. Xylocaine + 10 ml of Normal Saline and **Dexmedetomidine Group** (group D) received 20 ml of inj. Bupivacaine + 10 ml of inj. Xylocaine + 10 ml of Normal Saline + 1 µg/kg of inj. Dexmedetomidine. Both groups were compared for the time of onset of sensory and motor blocks, postoperative analgesia and haemodynamic changes. **Results:** The onset of sensory and motor blockade (2.9 ± 1.0 Vs 8.8 ± 2.22 min and 5.23 ± 1.14 Vs 10.86 ± 2.41 min, respectively) were significantly more rapid in the **D** group than in the **C** group ($p = 0.0001$). The duration of sensory and motor blockade (825 ± 133.83 Vs 412 ± 74.17 and 878.33 ± 166.23 Vs 409.33 ± 72.01 min respectively) were significantly longer in the **D** group than in the **C** group ($p = 0.0001$). The duration of analgesia (1448.66 ± 288.33 Vs 499 ± 78.79 min) was significantly longer in **D** group than in the **C** group ($p = 0.0001$). Systolic and diastolic blood pressure were lower in **D** group than **C** group during the period of anaesthesia from 30 to 120 minutes (in this period patients can be closely monitored and managed) ($p < 0.05$). Heart rate levels were also low in **D** group than **C** group during the period of anaesthesia from 15 to 120 minutes ($p < 0.05$). **Conclusion:** We conclude that the addition of dexmedetomidine to local anaesthetic mixture in infraclavicular brachial plexus block hastens the onset and prolong the duration of sensory and motor blocks, as well as the duration of postoperative analgesia.

Keywords: Infraclavicular brachial plexus block, dexmedetomidine, bupivacaine, postoperative analgesia.

*Address for Correspondence:

Dr. Prashant Lomate, Assistant Professor, Department of Anaesthesia, Bharati Vidyapeeth Deemed University Medical College and Hospital, Sangli, Maharashtra, INDIA.

Email: drprashantlomate@gmail.com

Received Date: 09/01/2015 Revised Date: 14/01/2015 Accepted Date: 19/01/2015

Access this article online

Quick Response Code:



Website:

www.statperson.com

DOI: 20 January 2015

INTRODUCTION

Brachial plexus block for upper limb surgery provides important advantages; compared with general anaesthesia

including excellent intraoperative and postoperative pain relief, reduced side effects etc. Various approaches are used for giving brachial plexus block. Each one has its own advantages and disadvantages¹. The vertical infraclavicular block has been associated with a minimal risk of pneumothorax and has a good reliability². Advantages of this approach are less painful arm positioning, easily palpable landmarks, homogenous spread of anaesthetic in a compact space containing cords and providing good quality of block^{3,4}. However advantages of these blocks are short-lived⁵ and limited by the short duration of action of local anaesthetics^{6,7}. So there has always been a continuous search for adjuvants that prolong the duration of anaesthesia. A variety of

perineural adjuvants⁸ including buprenorphine, clonidine, dexamethasone, magnesium, midazolam⁹⁻¹⁵ etc. have been used to prolong the duration of analgesia of nerve blocks with varying degrees of success. Dexmedetomidine- an α_2 adrenoceptor agonist has become the frequently used drug in anaesthesia practice due to its cardiostable, sedative, anxiolytic, analgesic, neuroprotective and anaesthetic sparing effects¹⁶. It's α_2/α_1 selectivity is 8 times more than clonidine; thus reducing the unwanted side effects involving α_1 receptors. It has been reported to improve the quality of intrathecal and epidural anaesthesia also^{17,18}. In humans, dexmedetomidine has been shown to prolong the duration of block and postoperative analgesia of various regional blocks¹⁹⁻²². The present study was planned with the aim to evaluate the effect of addition of dexmedetomidine to the local anaesthetics in infraclavicular brachial plexus block for upper limb orthopedic surgeries. The characteristics of blockade which were observed were - the onset of sensory and motor blocks, duration of sensory and motor blocks, duration of postoperative analgesia and haemodynamic parameters.

MATERIAL AND METHODS

This prospective randomized double blind study was conducted after obtaining permission from institutional authority and informed written consent from the patients. 60 patients of ASA grade I and II of either sex, aged

between 18 to 60 years, scheduled for surgeries on lower arm, elbow, forearm and hand were included in this study. Patients with known hypersensitivity to local anaesthetic drugs, uncontrolled diabetes mellitus, hypertension, peripheral neuropathy, hepatic and renal disease, pregnant patients or coagulopathy were excluded from the study. The patients were randomly divided into 2 groups by drawing out any one of the two labeled cards (**C** and **D**) from a sealed envelope. The anaesthetist performing the randomization and preparation of the drug solution was not involved in the process of performing blocks or in evaluation and recording of the study parameters and thus the study was double blinded. The composition of drugs in the two groups included as follows,

Statistical Analysis

Interval data are expressed as mean and standard deviation. Student's 't' test was used to compare the two groups. Chi square test was used for analysis of nonparametric data. A *p* value of < 0.05 was considered statistically significant.

RESULTS

Demographic profile

There was no statistically significant difference between the demographic profile (age, sex, height, weight), ASA grades and duration of surgery of the two groups. (Table 1)

Table 1: Demographic data of patients

Parameters	Group C (n = 30)	Group D (n = 30)
Age (years)	40.23 ± 13.24	34.23 ± 13.67
Male : Female	19 : 11	22 : 8
Height (cm)	163.6 ± 5.70	164.83 ± 5.53
Weight (kg)	56.2 ± 5.72	56.7 ± 5.87
Duration of surgery (min)	85 ± 23.76	92 ± 20.72

There was no significant difference between groups

Sensory block

The mean onset of sensory block was faster in group **D** than in group **C** (2.9 ± 1.0 Vs 5.23 ± 1.14 minutes respectively) (table 2). It was statistically significant ($p < 0.0001$). The duration of sensory block was longer in group **D** than in group **C** (825 ± 133.83 minutes Vs 412 ± 74.17 minutes respectively.) It was statistically significant ($p < 0.0001$).

Motor block

The mean onset of motor block was also faster in group **D** as compared to group **C**. (5.23 ± 1.14 Vs 10.86 ± 2.41 minutes respectively). It is statistically significant ($p < 0.0001$). The duration of motor block was also longer in group **D** than in group **C**. (878.33 ± 166.23 minutes Vs 409.33 ± 72.01 minutes respectively.) It was statistically significant ($p < 0.0001$).

Table 2: Comparison of Block characteristics of the two groups

Sr. No.		Group C	Group D	p value
1	Onset time of sensory block (minutes)	5.23 ± 1.14	2.9 ± 1.0	< 0.0001
2	Onset time of motor block (minutes)	10.86 ± 2.41	5.23 ± 1.14	< 0.0001
3	Duration of sensory block (minutes)	412 ± 74.17	825 ± 133.83	< 0.0001
4	Duration of motor block (minutes)	409.33 ± 72.01	878.33 ± 166.23	< 0.0001
5	Duration of analgesia (minutes)	499 ± 78.79	1448.66 ± 288.33	< 0.0001

(*p* value > 0.05 – statistically insignificant and *p* value < 0.001 – statistically significant)

Post-operative Analgesia

The duration of analgesia was significantly longer in group **D** as compared to group **C** (1448.66 ± 288.33 minutes Vs 499 ± 78.79 minutes respectively with p value

< 0.0001) Postoperative distribution of patients according to $VAS \geq 4$ (fig.1) shows that all patients in group **C** required rescue analgesia by 14 hours; whereas in group **D** the same was true only after 34 hours.

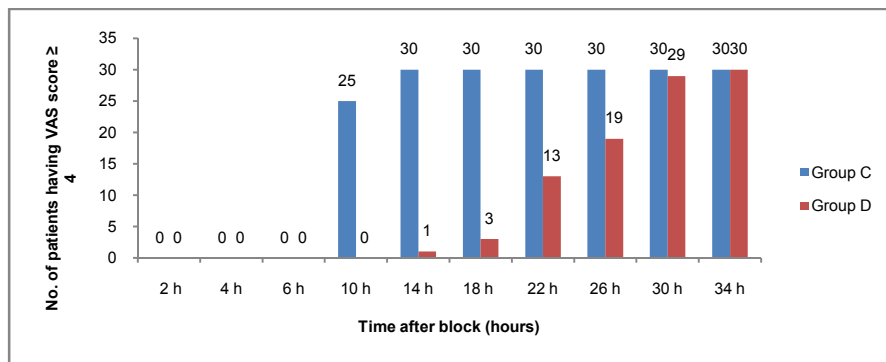


Figure 1: Postoperative distribution of patients according to visual analogue scale (VAS) ≥ 4

Haemodynamics

Systolic arterial blood pressure levels during the period of anaesthesia i.e. from 15 to 120 minutes were lower in group **D** than those in group **C**. ($p < 0.05$) But it was clinically insignificant. Diastolic arterial blood pressure levels during the period of anaesthesia i.e. from 60 to 120 minutes were also significantly lower in group **D** than

those in group **C**. ($p < 0.05$) (fig. 2) though it was clinically insignificant. Heart rate levels during the period of anaesthesia i.e. from 15 to 120 minutes were observed to be lower in group **D** than those in group **C** ($p < 0.05$). It was also clinically insignificant (fig.3). No patient developed bradycardia (i.e. heart rate < 50 / minute).

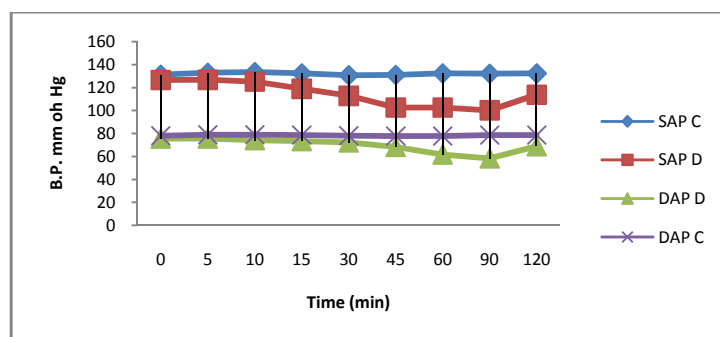


Figure 2: Systolic and Diastolic arterial blood pressure for two groups C and D

(SAP= systolic arterial blood pressure, DAP = diastolic arterial blood pressure)

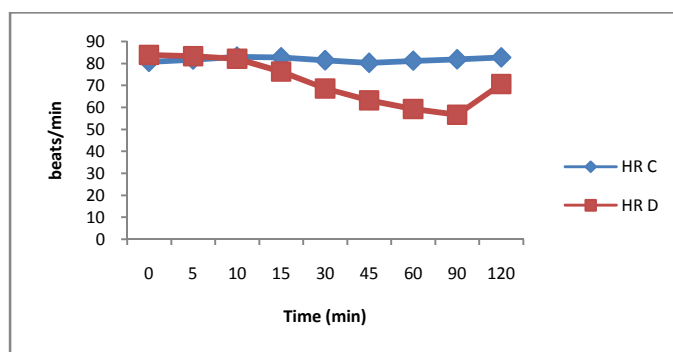


Figure 3: Comparison of heart rate in two groups C and D

No side effects like respiratory depression, nausea, vomiting were observed in any group. No patient in either group required general anaesthesia. Four patients in group **C** required sedation due to mild discomfort, but no patient in group **D** required sedation.

DISCUSSION

We designed this prospective randomized double blind study to evaluate the outcome of adding dexmedetomidine to local anaesthetics in infraclavicular brachial plexus block. Our study showed that addition of $1\mu\text{g} / \text{kg}$ of dexmedetomidine perineurally results in a significantly shorter onset time and prolonged duration of sensory and motor blocks. It also prolongs the time to first analgesic request. The efficacy of dexmedetomidine appears to be comparable with other adjuvants like buprenorphine^{9,22} and dexamethasone¹¹ and exceeds that of clonidine, magnesium and midazolam for brachial plexus block^{10,14}. Dexmedetomidine an α_2 agonist was first proposed as an adjuvant capable of prolonging duration of sensory and motor blocks produced by nerve blocks by Memis and colleagues¹⁹. Some trials have shown that perineural dexmedetomidine reduces onset time and prolongs duration of sensory and motor blocks^{20,21}. However other trials have demonstrated either a delay in sensory and motor block onset time²⁴ or no effect on sensory and motor block durations²⁵ with the use of perineural dexmedetomidine. Our study demonstrated that dexmedetomidine hastens the onset of action and duration of sensory-motor blocks of local anaesthetics when injected perineurally for infraclavicular brachial plexus block, which was statistically significant. Dexmedetomidine is an α_2 receptor agonist drug. It has both central and peripheral actions. Exact mechanism of action is not fully understood. High selectivity of dexmedetomidine to $\alpha_2\text{-A}$ receptors mediates its analgesic and sedative properties. The presence of dexmedetomidine at α_2 adrenergic receptors in the dorsal horn of spinal cord and locus ceruleus modulates release of substance P to produce analgesic effects^{26,27}. Several animal and human studies have proved the safety and efficacy of dexmedetomidine in various neuraxial and peripheral nerve blocks^{17,20,25}. Memics *et al* used a dexmedetomidine and xylocaine mixture in Bier's block and shown the improved quality of anaesthesia, good tolerance to tourniquet pain and reduced postoperative analgesic requirement. Esmaglu A *et al* performed the study and his results were the same²⁵. Abosedira MA compared the effect of adding either clonidine or dexmedetomidine to lidocaine for Bier's block and found that dexmedetomidine is superior to clonidine in respect to quality of anaesthesia and postoperative analgesia²⁸. In one study Brumett *et al* found that dexmedetomidine

enhances the duration of bupivacaine anaesthesia and analgesia of sciatic nerve in rats with no damage to nerve²⁹. While a number of studies suggest that it is protective against hypoxic ischaemic neuronal injury in rat and human neonatal asphyxia model³⁰⁻³⁶, dexmedetomidine has also been shown to cause moderate to severe demyelination in white matter when doses as high as $6.1\mu\text{g} / \text{kg}$ were administered epidurally in rabbits³⁷. In another study Brumett *et al* found that perineural dexmedetomidine when added to ropivacaine causes a dose dependant increase in the duration of blockade of sciatic nerve in rat³⁸. Kousugi *et al* found that high concentrations of dexmedetomidine inhibits compound action potential in frog sciatic nerve without α_2 adrenoceptor activation³⁹. Esmaglu *et al* found in his study that dexmedetomidine when added to levobupivacaine for axillary brachial plexus block shortens the sensory-motor onset time, extends sensory-motor block durations and also extends the analgesia periods²⁰. In one study obayah *et al* reported that addition of dexmedetomidine to bupivacaine for greater palatine nerve block prolongs postoperative analgesia after cleft palate repair²¹. Finally considerable difference existed in the doses of perineural dexmedetomidine. Doses varied between $30\mu\text{g}$, $100\mu\text{g}$, $0.75\mu\text{g} / \text{kg}$ and $1\mu\text{g} / \text{kg}$ ^{21,24,40,41}. Despite these variations, it is nonetheless noteworthy that significantly prolonged duration of sensory and motor blocks and also time for first analgesic request were achieved even with the lowest doses i.e. $30\mu\text{g}$. We used $1\mu\text{g} / \text{kg}$ dose of dexmedetomidine and found the significant extension of block duration without any significant side effects. Dexmedetomidine may lead to side effects such as bradycardia and hypotension along with its effects such as sedation and anxiolysis⁴². The side effects are mostly dose dependant. In our study pulse rate and blood pressure were on lower side 30 minutes after the block but without any bradycardia and hypotension. We used dexmedetomidine in the dose of $1\mu\text{g} / \text{kg}$ according to the previous studies. A volume of 40 ml of local anaesthetic agents was taken, as this volume was associated with more volume spread for brachial plexus blocks found by Winnie and colleagues⁴³. We found that onset time for sensory and motor blocks were significantly shortened in group **D** than in group **C**. The durations of sensory and motor blocks and postoperative analgesia were also significantly prolonged in group **D**. Our findings are comparable with previous studies²⁰. But we found that the durations of sensory-motor blocks and postoperative analgesia were comparatively more in our study than any other study. All patients in both groups were haemodynamically stable although the pulse rate and blood pressure were on lower side in group **D**; but it was clinically insignificant. Further

studies are needed to determine the side effects and safety dose of dexmedetomidine; and to reduce the volume of local anaesthetics with the use of ultrasound. Further studies are also necessary to see its effects in patients of same gender and / or of same weights. The easy availability and lack of significant side effects like respiratory depression makes dexmedetomidine an attractive choice as an adjuvant to local anaesthetics in infraclavicular brachial plexus block for prolongation of postoperative analgesia.

CONCLUSION

From the aforesaid study and results obtained from it, we conclude that the addition of 1µg / kg dexmedetomidine as an adjuvant to local anaesthetics for infraclavicular brachial plexus block hastens the onset time of sensory-motor blocks, extends the duration of sensory-motor blocks and also significantly prolongs the duration of postoperative analgesia. The addition of dexmedetomidine in brachial plexus block has no significant side effects. However blood pressure and heart rate remains on lower side although clinically insignificant. In the light of haemodynamic side effects, though not significant, further studies are required for authentication.

REFERENCES

1. Ertug Z, Yegin A, Ertem S, Sahin N, Hadimioglu N, Docemeci L, *et al.* Comparison of two different techniques for brachial plexus block: infraclavicular versus axillary technique. *Acta Anaesthesiol Scand* 2005; 49:1035-9.
2. Raj P, Montgomery SJ, Nettles D, Jenkins MT. infraclavicular Brachial plexus Block- A new approach. *Anesth Analg* 1973; 52:897-904.
3. Kilka HG, Geiger P, Mehrkens HH. Infraclavicular vertical brachial plexus blockade: A new technique of regional anesthesia. *Anesthetist* 1995; 44:339-44.
4. Lanz E, Thesiss D, Jancovic D. The extent of Blockade Following Various techniques of brachial plexus block. *Anesth Analg* 1983; 62:55-58.
5. McCartney CJ, brull R, Chan VW, *et al.* Early but no long term benefits of regional compared with general anesthesia for ambulatory hand surgery. *Anesthesiology* 2004; 101:461-7.
6. Cavino BJ, Wildsmith JA. Clinical pharmacology of local anesthetic agents. In:Cousins MJ, Bridenbaugh PO,eds. *Neural Blockade in Clinical Anesthesia and Management of Pain*. Philadelphia, PA:Lippincott-Raven, 1998;97-128.
7. Kuzma PJ, Kline MD, Calkins MD, Staats PS. Progress in the development of ultra-long- acting local anesthetics. *Reg Anesth* 1997; 22:534-51.
8. Yaksh TL, Ilfeld BM, Wiese AJ, perineural local anesthetic and adjuvant action: the meaning of ex-vivo data set for efficacy and safety. *Reg Anesth Pain Med* 2012; 37:366-8.
9. Candilo KD. Buprenorphine added to local anesthetic for axillary brachial plexus block prolongs postoperative analgesia. *Reg Anesth Pain Med* 2002; 27:162-7.
10. McCartney CJ, Duggan E, Apatu E. Should we add clonidine to local anesthetic for peripheral nerve blockade? A qualitative systematic review of literature. *Reg. Anesth Pain Med* 2007; 32:330-8.
11. Parrington S, O'Donnell D, Chan VW, *et al.* Dexamethasone added to mepivacaine prolongs the duration of analgesia after supraclavicular brachial plexus blockade. *Reg. Anesth Pain Med* 2010; 35:422-6.
12. Buvanendran A, McCarthy RJ, Kroin JS, Leong W, Perry P, Tuman KJ. Intrathecal magnesium prolongs fentanyl analgesia: a prospective randomized, controlled trial. *Anesth Analg* 2002; 95:661-6.
13. Murali Krishna T, Panda NB, Batra YK, Rajeev S. Combination of low doses of intrathecal ketamine and midazolam with bupivacaine improves postoperative analgesia in orthopedic surgery. *Eur J Anesthesiol* 2008; 25:299-306.
14. Laiq N, Khan MN, Arif M, Khan S, Midazolam with bupivacaine for improving analgesia quality in brachial plexus block for upper limb surgeries. *J Coll Physicin Surg Pak* 2008; 18:674-8.
15. Gabriel JS, Gordin V. Alpha 2 agonist in regional anesthesia and analgesia. *Curr Opin Anesthesiol* 2001; 14:751-3.
16. Panzer O, Moitra V, Sladen RN. Pharmacology of sedative-analgesic agents: Dexmedetomidine, remifentanyl, ketamine, volatile anesthetics, and the role of peripheral mu antagonists. *Crit Care Clin* 2009; 25:451-69.
17. Kanazi GE, Aouad MT, Jabbour-Khoury SI, Al Jazzar MD, Alameddine MM, Al-Yaman R, Bulbul M, Baraka AS. Effect of low dose dexmedetomidine or clonidine on the characteristics of bupivacaine spinal block. *Acta Anaesth Scand* 2006; 50:222-7.
18. Congedo E, Sgreccia M, De Cosmo G. New drugs for epidural analgesia. *Curr Drug Targets* 2009; 10:696-706.
19. Memis D, Turan A, Karamanlioglu B, Pamukcu Z, Kurt I. Adding dexmedetomidine to lidocaine for Intravenous Regional Anaesthesia. *Anesth Analg* 2004; 98:835-40.
20. Esmaoglu A, Yegenoglu F, Akin A, Turk CY. Dexmedetomidine added to levobupivacaine prolongs axillary brachial plexus block. *Anaesthe Analg* 2010; 111:1548-51.
21. Obayah GM, Refaie A, Aboushanab O, Ibraheem N, Abdelazees M. Adding dexmedetomidine to bupivacaine for greater palatine nerve block prolongs postoperative analgesia after cleft palate repair. *Eur J Anaesthesiol* 2010; 27:280-4.
22. Jadon A, Panigrahi MR, Parida SS, Chakraborty S, Agrawal PS, Panda A. Buprenorphine improves the efficacy of bupivacaine in nerve plexus block: A double blind randomized evaluation in subclavian perivascular brachial block. *J Anaesth Clin Pharmacol*. 2009;25(2):207-10
23. Gaumann D, Forster A, Griessen M, Habre W, Poinot O, Della Santa D. Comparison between clonidine and epinephrine admixture to lidocaine in brachial plexus block. *Anesth Analg* 1992; 75:69-74.

24. Gandhi R, Shah A, Patel I. Use of dexmedetomidine along with bupivacaine for brachial plexus block. *National J Med Res* 2012; 2:67-9.
25. Esmaoglu A, Mizrak A, Akin A, Turk Y, Boyaci A. Addition of dexmedetomidine to lidocaine for intravenous regional anesthesia. *Eur J Anaesthesiol* 2005; 22:447-51.
26. Eisenach JC, De Kock M, Klimscha W. Alpha (2) - Adrenergic agonists for regional anesthesia. A clinical review of Clonidine (1984-1995). *Anesthesiology* 1996; 85:655-74.
27. Guo TZ, Jiang JY, Buttermann AE, Maze M. Dexmedetomidine injection into the locus ceruleus produces Antinociception. *Anesthesiology* 1996; 84:873-81.
28. Abosedira MA. Adding Clonidine or dexmedetomidine to lidocaine during Bier's block: a comparative study. *J M Sci* 2008; 8:660-4.
29. Brummet CM, Norat MA, Palmisano JM, Lydic R. Perineural administration of dexmedetomidine in combination with bupivacaine enhances sensory and motor blockade in Sciatic nerve block without inducing neurotoxicity in rat. *Anesthesiology* 2008; 109:502-11.
30. Hoffmen WE, Kochs E, Werner C, Thomas C, Albrecht RF. Dexmedetomidine improves neurologic outcome from incomplete ischaemia in rat reversal by the alpha 2- adrenergic antagonist atipamezol. *Anesthesiology* 1991; 75:328-32.
31. Maier C, Steinberg GK, Sun GH, Maze M. Neuroprotection by the alpha 2- adrenoceptor agonist dexmedetomidine in a focal model cerebral ischaemia. *Anesthesiology* 1993; 79:306-12.
32. Halonen T, Kotti T, Tuunanen J, Toppinen A, Miettinen R, Riekkinen PJ. Alpha 2- adrenoceptor agonist, dexmedetomidine protects against kainic acid- induced convulsions and neuronal damage. *Brain Res* 1995; 693:217-24.
33. Kuhmonen J, Pokorny J, Miettinen R, et. al. Neuroprotective effects of dexmedetomidine in the gerbill hippocampus after transient global ischaemia. *Anesthesiology* 1997; 87:371-7.
34. Jolkkonen J, Puurnen K, Koistinaho J, et al. Neuroprotection by the alpha-2 adrenoceptor agonist, dexmedetomidine, in rat focal cerebral ischaemia. *Eur J Pharmacol* 1999; 372:31-6.
35. Laudenbach V, Mantz J, Lagercrantz H, Desmonts JM, Evrard P, Gressens P. Effects of alpha-2 adrenoceptor agonist on perinatal excitotoxic brain injury: Comparison of clonidine and dexmedetomidine. *Anesthesiology* 2002; 96:134-41.
36. Ma D, Hossain M, Rajkumaraswamy N, et.al dexmedetomidine produces its neuroprotective effect via the α_2 -A adrenoceptor subtype. *Eur J Pharmacol* 2004; 502:87-97.
37. Konacki S, Adanir T, Yilmaz G, Rezanko T. The efficacy and neurotoxicity of dexmedetomidine administered via the epidural route. *Eur J Anesthesiol* 2008; 25:403-9.
38. Brummet CM, Padda AK, Amodeo FS, Welch KB, Lydic R. Perineural dexmedetomidine added to ropivacaine causes a dose dependant increase in the duration of thermal antinociception in sciatic nerve block in rat. *Anesthesiology* 2009; 111:111-9.
39. Kosugi T, Mizuta K, Fujita T, Nakashima M, Kumamoto E. High concentration of dexmedetomidine inhibit compound action potential in frog sciatic nerve without α_2 adrenoceptor activation. *Br J Pharmacol*. 2010; 160:1662-76.
40. Ammar AS, Mahmoud KM. Ultrasound-guided single injection infraclavicular brachial plexus block using bupivacaine alone or combined with dexmedetomidine for pain control in upper limb surgery: a prospective randomized controlled trial. *Saudi J Anaesth* 2012; 6:109-14.
41. Kaygusuz K. Effects of adding dexmedetomidine to levobupivacaine in axillary brachial plexus block. *Curr Ther Res Clin Exp* 2012; 73:103-11.
42. Talke P, Lobo E, Brown R. Systemically administered α_2 -agonist induced peripheral vasoconstriction in humans. *Anesthesiology* 2003; 99:65-70.
43. Winnie AP, Radonjic R, Akkineki SR, et al Factors influencing distribution of local anesthetic injected into brachial plexus sheath. *Anesth. Analg* 1979; 58:225-234.

Source of Support: None Declared
Conflict of Interest: None Declared