

# Phimosis in children: Conservative treatment using a topical steroid

Anita Jagdish Kandi<sup>1\*</sup>, Venkat Arjunrao Gite<sup>2</sup>, Anagha S Varudkar<sup>3</sup>

{<sup>1</sup>Assistant Professor, <sup>3</sup>Professor, Department of Surgery}{<sup>2</sup>Assistant Professor, Department of Urology}  
Government Medical College, Aurangabad, Maharashtra, INDIA.

Email: [drsyedobaid@gmail.com](mailto:drsyedobaid@gmail.com)

## Abstract

**Introduction:** Phimosis or inability to retract the foreskin in the majority of neonates is because of natural adhesions exist between the prepuce and the glans. Circumcision is often regarded as a minor surgical procedure but there is probably more complication associated with this operation. In cases of pathologic phimosis, surgical correction is the standard treatment. However, in recent years, the topical application of steroids provides an alternative to the management of this disease. **Aims and objectives:** To evaluate the efficacy of topical steroid betamethasone (0.05%) in management phimosis. **Materials and methods:** 50 pediatric patients of phimosis attending the surgery outpatient department and patients referred from pediatric outpatient department as well as Indoor ward were included in the study. The phimosis was graded by using Kikiros grading system. All patients underwent treatment with application of topical steroid betamethasone 0.05% thrice daily after washing or bathing for 4 weeks to the foreskin. After the foreskin become retractable, patients / parents were asked to retract the foreskin gently without causing any pain. When the phimosis didn't resolve then patients were offered another course of two weeks. A final assessment of the grading was done at completion of 6 weeks course. All patients were followed up at 8, 10, and 12 weeks respectively after completion of treatment. **Results:** The mean age of children in the study was  $6.3 \pm 0.43$  years. Majority of the children were having grade V phimosis (86%) and it was followed by grade IV (14%). Response rate of topical steroid betamethasone 0.05% at 4<sup>th</sup> week was 80%. Out of 8 patients who did not respond at 4<sup>th</sup> week were given additional 2 week treatment and 6 patients responded. First follow up was done at 8<sup>th</sup> week and the treatment response rate was maintained (92%). The response rate was maintained at 92% till the follow-up was done at 12<sup>th</sup> week. **Conclusion:** Thus in the end we conclude that topical treatment of phimosis with corticosteroids is simple and efficient treatment modality.

**Key words:** Phimosis, betamethasone 0.05%, response rate.

## \*Address for Correspondence:

Dr. Anita Jagdish Kandi, Assistant Professor, Department of Surgery, Government Medical College, Aurangabad, Maharashtra, INDIA.

Email: [drsyedobaid@gmail.com](mailto:drsyedobaid@gmail.com)

Received Date: 08/01/2015 Revised Date: 14/01/2015 Accepted Date: 21/01/2015

Access this article online	
Quick Response Code:	Website: <a href="http://www.statperson.com">www.statperson.com</a>
	DOI: 22 January 2014

## INTRODUCTION

The term Phimosis is derived from the Greek word phimos which means muzzle. Phimosis usually describes “a covered glans that cannot be retracted.”<sup>1</sup> Phimosis or inability to retract the foreskin in the majority of neonates is because of natural adhesions exist between

the prepuce and the glans. Pathological phimosis is rare and the causes are varied. Some cases may arise from inflammation of the glans penis, perhaps due to inappropriate efforts to retract an infant's foreskin. Other cases of non-retractile foreskin may be caused by preputial or narrowness that prevents retraction, by fusion of the foreskin with the glans penis in children, or by which prevents retraction. In some cases a cause may not be clear, or it may be difficult to distinguish physiological phimosis from pathological if an infant appears to be in pain with urination or has obvious ballooning of the foreskin with urination or apparent discomfort. However, ballooning does not indicate urinary obstruction.<sup>2</sup> Phimosis can cause ballooning during micturition, discomfort with voiding, infection, and pain on erection. In the long term, renal damage and BXO can occur and carcinoma of the penis has been thought to be more common when phimosis is present.<sup>3</sup> Diagnosis of

phimosis is primarily clinical and no laboratory tests or imaging investigations are required. These may be required for associated urinary tract infections or skin infections.<sup>4</sup> There are different ways of managing phimosis surgically including routine circumcision, sutureless circumcision, preputioplasty and its modifications, dilatation with a balloon or artery forceps and forced retraction with local, general or no anaesthetic. Circumcision is often regarded as a minor surgical procedure but there is probably more complication associated with this operation. In cases of pathologic phimosis, surgical correction is the standard treatment. However, in recent years, the topical application of steroids provides an alternative to the management of this disease.<sup>5</sup> Thus the present study was undertaken to study the efficacy of topical steroid in the management of phimosis.

### AIMS AND OBJECTIVES

To evaluate the efficacy of topical steroid betamethasone (0.05%) in management phimosis.

### MATERIALS AND METHODS

The present prospective study was conducted in the department of surgery from November 2010 to December 2012 at Government medical college and hospital, Aurangabad. All the pediatric patients of phimosis attending the surgery outpatient department and patients referred from pediatric outpatient department as well as Indoor ward were included in the study. Thus a total 50 patients were enrolled in the study.

As all the patients were of pediatric age group, informed consent was taken from their parents or guardian. The Parents and guardians were explained the course of duration and follow-up for treatment. The basic information and clinical findings were recorded on a prestructured proforma. The phimosis was graded by using Kikiros grading system<sup>6</sup>.

- Grade 0: full retractability,
- Grade I: full retraction but tight behind glans,
- Grade II: partial exposure of glans,
- Grade III: partial retraction with meatus just visible,
- Grade IV: slight retraction but neither meatus nor glans visible, and
- Grade V: absolutely no retraction.

All patients underwent treatment with application of topical steroid betamethasone 0.05%. Parents and gaurdians were taught to apply betamethasone cream 0.05 % thrice daily after washing or bathing for 4 weeks to the foreskin. After the foreskin become retractable, patients / parents were asked to retract the foreskin gently without causing any pain.

Patients were followed up every weekly and chart was kept showing the variation in grading. When the phimosis didn't resolve then patients were offered another course of two weeks. The patients were examined- for phimosis using the grading same definition as before. The criterion used for response to steroid treatment with betamethasone 0.05% was fully retractable prepuce. Any presence of possible local and systemic side effects was also looked for and was noted. A final assessment of the grading was done at completion of 6 weeks course. All patients were followed up at 8, 10, and 12 weeks respectively after completion of treatment.

### RESULTS

**Table 1:** Agewise distribution of patients of phimosis

Age Group	No. of Patients	Percentage
Up to 5 yeas	30	60
5 – 10 years	12	24
> 10 years	08	16
<b>Total</b>	<b>50</b>	<b>100%</b>

It was observed that majority (60%) of the children with phimosis were less than 5 years old. The mean age of children in the study was  $6.3 \pm 0.43$  years.

**Table 2:** Distribution of patients according to Kikiros Grade of Phimosis

Grade	No. of Patients	Percentage %
Grade 0	0	0%
Grade I	0	0%
Grade II	0	0%
Grade III	0	0%
Grade IV	7	14%
Grade V	43	86%
<b>Total</b>	<b>50</b>	<b>100%</b>

Phimosis was grade by using Kikiros grading system. It was observed that majority of the children were having grade V phimosis (86%) and it was followed by grade IV (14%). No child was having grade I, II and III phimosis in the present study.

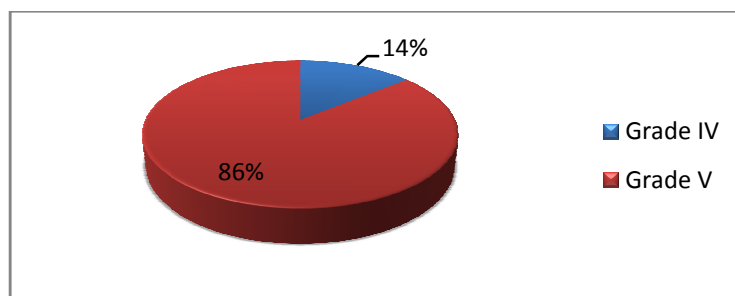


Figure 1: Distribution of patients according to Kikiros Grade of Phimosis

Table 3: Distribution of children according to response to topical betamethasone 0.05%

Follow up	Grade						Lost to visit	Response rate
	0	I	II	III	IV	V		
Before treatment	0	0	0	0	7	43	NA	NA
2 <sup>nd</sup> week	0	0	2	31	16	0	1	00
4 <sup>th</sup> week	40	0	4	4	0	0	2	80%
6 <sup>th</sup> week	46	0	2	0	0	0	2	92%
8 <sup>th</sup> week	46	0	1	1	0	0	2	92%
10 <sup>th</sup> week	46	0	0	0	2	0	2	92%
12 <sup>th</sup> week	46	0	0	0	1	1	2	92%

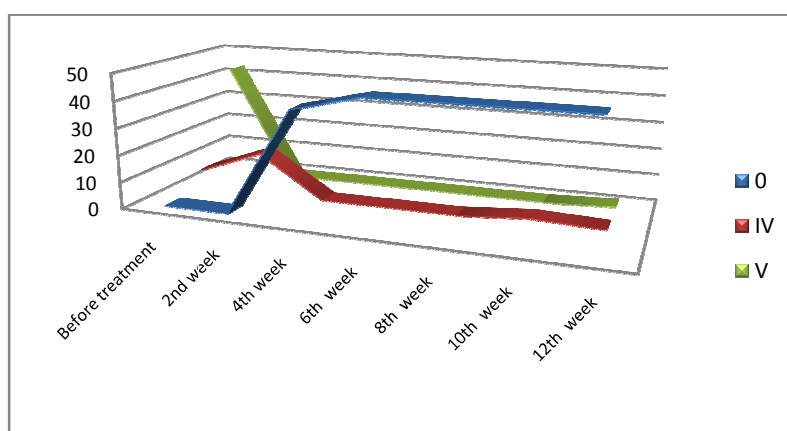


Figure 2: Response to topical betamethasone 0.05%

After the 2 weeks of the treatment there was improvement in the signs, 62% were in grade III and 32% in grade IV except 1 patient who lost to the visit. After completing 4 weeks of treatment 40 (80%) were in grade 0. Out of the 50 patients 2 were lost to the visit at 4th week. Out of 8 patients who did not respond at 4th week were given additional 2 week treatment and 6 patients responded (additional response rate 74%). First follow up was done at 8th week and the treatment response rate was maintained (92%). Second follow up at was done after 10 week and the response rate was maintained (92%). Third follow up was done after 12th week and it was observed that response rate was maintained at 92%. It was also observed that in Grade IV and V there was one patient each.

## DISCUSSION

Present study was carried out among the 50 children of phimosis to study the efficacy of topical steroid Betamethasone 0.05%. It was observed that 60% of the children with phimosis were less than 5 years old. The mean age of children in the study was  $6.3 \pm 0.43$  years. Wai-Tat Ng et al<sup>7</sup> in their prospective study observed the mean age was 5.7 years whereas Webster TM, Leonard MP<sup>8</sup> reported mean age of 7.4 years in their study. Severity of phimosis was classified by using Kikiros grading system. And it was observed that majority of the children were having grade V phimosis (86%) and it was followed by grade IV (14%). No child was having grade I, II and III phimosis in the present study. Kuehhas FE et al<sup>9</sup> in their study of 55 patients reported 16(44.4%) patients of grade IV and 7(19.4%) patients were of grade V. B.K Rai<sup>10</sup> in his study of 42

patients observed that 24(57.14%) patients had grade V and 18(42.85%) had grade IV Phimosis. All the 50 patients in the study were treated with application of topical steroid betamethasone 0.05% for weeks and response was noted. It was seen those after the 2 weeks of the treatment there was improvement in the signs. After completing 4 weeks treatment response rate was 80%. Two patients were lost to the visit. Remaining 8 patients were given additional treatment for 2 weeks and out of them 6 patients showed improvement in the signs. Thus the total response rate at the end of 6<sup>th</sup> week was 92%. The follow up was done till the completion of 12 weeks and the response rate was maintained at 92%. Orsola et al<sup>11</sup> in his study of 137 patients reported response rate 82% at 4<sup>th</sup> week and 90% at 6<sup>th</sup> week. Wat-Tat Ng et al<sup>7</sup> in their study of 83 patients reported 58% success rate at the end of 4 week and 84% at the end of 6 week of treatment using 0.05% betamethasone. Elmore J M et al<sup>12</sup> in his study reported success rate of 74% after 4 weeks and 92% after 6 weeks of treatment. Lee K S et al<sup>13</sup> Flavio de Oliveira Pileggi et al<sup>14</sup> and Peter D. Metcalfe<sup>15</sup> **reported 85%, 96.43% and 75% of success rate in their study.** Surgical correction has been standard treatment modality for many years in the management of childhood phimosis. In this age group, circumcision requires general anesthesia. Although a low complication rate is associated with circumcision, some complications such as bleeding, meatitis with meatal stenosis can occur.<sup>16</sup> Surgical alternatives to circumcision, such as preputial plasty, also require anesthesia and have up to 4% recurrence rate.<sup>17</sup> In the recent years, topical application of steroids for treating phimosis has provided to be an effective nonsurgical treatment.<sup>18</sup> Australasian Association of Pediatric Surgeons has also recommended this treatment for the management of phimosis.<sup>19</sup> Various studies using topical steroids for phimosis have demonstrated a high success rate, ranging from 75% to 96%. In the present study we also observed the success rate of 92%.

## CONCLUSION

Thus in the end we conclude that topical treatment of phimosis with corticosteroids is simple and efficient treatment modality.

## REFERENCES

- Hodges FM. Phimosis in antiquity. *World J Urol* 1999;17(3):133-6.
- Babu R, Harrison SK, Hutton KA. Ballooning of the foreskin and physiological phimosis: is there any objective evidence of obstructed voiding? *BJU Int* 2004.
- Gairdner D (1949) The fate of the foreskin. *Br Med J* 2: 1433-1437
- Jorgensen ET, Svensson A. The treatment of phimosis in boys, with a potent topical steroid (clobetasol propionate 0.05%) cream. *Acta Dermato-Venerologica* 1993;73(1):55-56.
- Deibert G.A. The separation of the prepuce in the human penis. *Anat Rec* 1933, 57:387-389.
- Kikiros CS, Beasley S W, Woodward AA, The response of phimosis to local steroid application. *Ped sury mt* 1993; 8:329-32.
- Wai-Tat Ng, Ning Fan et al ... Julio Cesar Morales Concepcion, Emilio Cordie s Jackson et al Phimosis, where there was discomfort, pain or other problems, it is true that there was 138 boys who were prescribed 0.05% betamethasone ointment (Diprocil) during 1 August 2001-31 July 2004.
- Webster TM, Leonard MP "Topical steroid therapy for Phimosis. *J. Urol.* 2002 Apr, 9(2):1492-5.
- Kuehhas FE, Miernik A, Sevcenco S, Tosev G, Weibl P, Schoenthaler M, et al. Predictive power of objectivation of phimosis grade on outcomes of topical 0.1% betamethasone treatment of phimosis. *Urology* 2012;80:412-6.
- BK Rai Department of General Practice & Emergency Medicine Nepal is an effective alternative to circumcision for the treatment of infant and childhood phimosis. *Health Renaissance*, September-December 2010; Vol 8 (No.3); 176-180.
- Orsola A, Caffaratti J, Garat JM. Department of Pediatric Urology 2000 Aug 1;56(2):7-10. Conservative treatment of phimosis in children using topical steroid.
- Elmore JM, Baker LA, Snodgrass WT. "Topical steroid therapy as an Alternative to circumcision for Phimosis in boys younger than 3 years. *J.Urol.* 2002 pct, 168(4):1746-5.
- Lee KS, Koizumi T, Nakatsuji H; et al. Treatment of Phimosis with Betamethasone ointment 0.10% in children" 2001 Sep.9, 2(6):619-23
- Flavio de Oliveira Pileggi. m moisturizing cream (placebo) for the treatment of phimosis. *Children aged Journal of Pediatric Surgery* (2007) 42, 1749-1752
- Peter D. Metcalfe, Remon Elyas. Foreskin management. *Can Fam Physician* 2010;56:e290-5
- Bloom D.A., Wan J. and Key D. (1992) Disorders of the male external genitalia and inguinal canal. In: Kelalis P.P., King L.R. and Belman A.B. (Eds.) *Clinical Pediatric Urology*. Philadelphia: WB Saunders.
- Cuckow P.M., Rix G. and Mouriquand P.D. Preputial plasty: a good alternative to circumcision. *J Pediatr Surg* 1994, 29:561-563.
- Jorgensen E.T. and Svensson A. The treatment of phimosis in boys, with a potent topical steroid (clobetasol propionate 0.05%) cream. *Acta Derm Venereol* 1993, 73:55-56.
- Australasian Association of Paediatric Surgeons: Guidelines for Circumcision. Hersion, Queensland, Australia, Australasian Association of Paediatric Surgeons, April 1996.

Source of Support: None Declared  
Conflict of Interest: None Declared