

The Pelger-Huet anomaly and prevalence of megaloblastic anemia in tribal population of Madhya Pradesh

Ajit Saluja¹, P L Dhand², Pragati Mamgain³, V K Mahadik⁴, Yogesh Patle^{5*}

¹Associate Professor, Department of Pathology, People's College of Medical Sciences and Research Centre, Bhopal, Madhya Pradesh, INDIA.

²Professor and HOD, ³P.G. Student, ⁴Medical Director, Department of Pathology, R.D. Gardi Medical College, Ujjain -456006, INDIA.

Email: drygpatele1983@gmail.com

Abstract

A study was carried out in Jhabua district of Madhya Pradesh to know the incidence of Pelger- Huet anomaly of leucocytes and prevalence of megaloblastic anemia among the Tribal population. Prevalance of megaloblastic anemia is very common among the tribals. More than 30% cases were observed in population of 10,000 during our study, out of which 6 were found to be suffering from actual Pelger- Huet anomaly and rest were having acquired features of megaloblastic anemia. The significance of these finding has been discussed. **History:** Pelger - Huet anomaly of leucocyte was first, described by Pelger (1928) and confirmed by Hut (1931) as a familial anomaly of leucocyte. The nuclei of granulocytes including eosinophils and basophils are either ovoid, round, rod or pea- nut-shaped or bilobed i.e. dumbbell or have spectacle appearance. The chromatin of these nuclei including lymphocytes and monocytes is unusually coarse, intensely basophilic and densely clumped giving pitted appearance the nuclear outline is clear. No immature granulocytes or red blood cells are found in peripheral blood. Thrombocytes are normal (Rosse And Gurney, 1959). They provide excellent Markers for genetic and other studies and also as a mean to study the survival of transfused leukocytes (Rosso and Gurney.1959)

Keywords: megaloblastic anemia, Pelger - Huet anomaly.

* Address for Correspondence:

Dr. Yogesh Patle, People's College of Medical Sciences, Bhopal, Madhya Pradesh, INDIA.

Email: drygpatele1983@gmail.com

Received Date: 25/12/2014 Revised Date: 29/12/2014 Accepted Date: 01/01/2015

Access this article online	
Quick Response Code:	Website: www.statperson.com
	DOI: 02 January 2015

INTRODUCTION

Incidence of megaloblastic anemia and Pelger Huet anomaly is a very common feature in the tribal population because of basic vitamin B12 and folate deficiency due to dietary habits. The reason for high incidence of Pelger-Huet anomaly in aboriginal tribes may apparently appear to be due to consanguineous marriages amongst its pure racial stock. They have remained confined to primitive dwellings in forest and hills and no social; or cultural admixture took place with other Aryan races in India. This might have resulted in persistence, segregation and propogation of this leucocyte anomaly amongst these

Bhils, Bhilala and Kathhiwar scheduled tribes. The basic clinicopathological manifestation of PelgerHuet anomaly is the presence of an oval, indented or bilobed ("prince-nez") nucleus in the neutrophil polymorphonuclear leukocytes which replaces the normal nuclear segmentation of these cells (Pelger). It is inherited as an autosomal dominant characteristic (Huet), the incidence being 1 in 6000 of the population (Davidson). By contrast, megaloblastic anemia is characterized by increase in the number of lobes in neutrophil, cabot's rings, basophilic stippling, Howel Jolly bodies. The combination of megaloblastic anemia in a family with the Pelger-Huet anomaly enabled us to observe the effect of megaloblastic process on the morphology of the cells exhibiting PelgerHuet trait. This paper reports are observational.

MATERIALS AND METHODS

The material consisted of 10000 peripheral blood smears of local tribal population of Jhabua and Alirajpur. All smears were drawn from peripheral blood and stained with Leishman's Stain. In all cases, lobe count of neutrophils was done by Cooke and Ponder modification of Ameth (1955) method i.e. neutrophils were classified into five groups:

1. One lobe.. No Filament
2. Two lobes..One Filament
3. Three lobes..Two Filaments
4. Four lobes..Three Filaments
5. Five or more lobes..Four Filaments or more.

Modus Operandi of Treatment

The patients were treated with monthly injections of 200 microgram of vitamin B12. After treatment course, the

stained blood showed the disappearance of the three and four lobed neutrophils which had been present before treatment with vitamin B12 and their replacement by neutrophils with their one or two lobes are seen in Pelger – Huet anomaly.

In this study a care was taken, whether suffering population has been treated fully, partially or untreated.

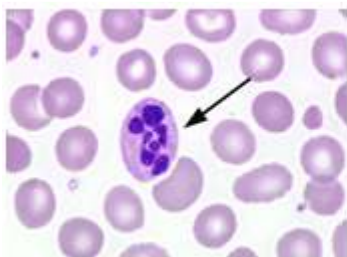


Figure 1: Peripheral blood film before treatment with vitamin B12.

The neutrophil shows hypersegmentation and red cell shows variation in size with tendency to macrocytosis.

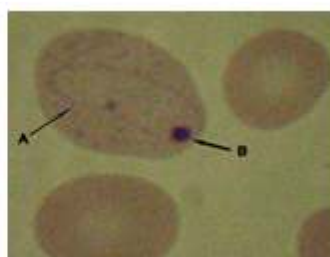


Figure 2: Peripheral blood A. Cabot's Rings

B. Howell Jolly Bodies in megaloblastic anemia

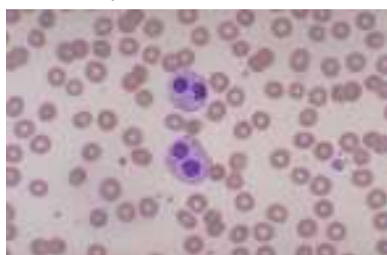


Figure 3: Peripheral blood film after treatment with vitamin B12 showing Pelger – Huet anomaly

Table 1: Comparative average percentage of lobes in neutrophil

Category of population	No. of Cases	Uni.	Bi.	Tri.	Tetra.	Penta.
Tribal population (Before Treatment)	10000	8	22	35	15	20
Tribal population (After Treatment)	10000	8	34	35	15	8

Table 1 shows that there is a significant variations in percentage of lobes in different categories of population after treatment with vitamin B12.

Incidence of Pelger-Huet anomaly The present study revealed 30% cases of Pelger-Huet anomaly of leukocytes amongst 10000 patients.

Table 2: Incidence of Pelger-Huet anomaly in the study population of tribals

No. of cases of Pelger –Huet anomaly detected	3000
No. of cases suffering from actual Pelger –Huet anomaly	6
No. of cases having acquired features of megaloblastic anemia	2994

Pelger- Huet anomaly of leukocyte was encountered in 6 individuals amongst a total of 10,000 Tribals. No such anomaly was detected by other local population of surrounding areas. The percentage of unilobed was 8 percent, bilobed 22 percent, trilobed were 35 percent, tetra-lobed 15 percent, penta-lobed 20 percent. However after treatment with vitamin B12 four and five lobed neutrophils changed towards bi-lobed. All 6 cases showed classical heterozygote type of Pelger-Huet anomaly. Neutrophils: The nuclei in bi-lobed neutrophils were both asymmetrical or symmetrical. In symmetrical bi-lobed

neutrophils, the two lobes were round and joined by chromatin strand. They are also described as “Pince-Nez” form. The asymmetrical lobes of neutrophils revealed marked. Variation in size and shape of both lobes. The uni-lobed neutrophils showed ovoid, indented and rod shaped nucleus. The present study reveals the existence of Pelger-Huet anomaly of leukocytes amongst tribal population of Jhabua. All 6 cases Pelger-Huet anomaly of conform to the criteria laid down for its diagnosis by Undritz (1939), Davidson (1961) and Rose and Gurney (1959) The nuclear chromatin revealed condensation and

clumping which was not only confined to neutrophils but also seen in eosinophils, lymphocytes and monocytes. The Pelger-Huet anomaly has been carefully distinguished from pseudo-Pelger-Huet changes which have been described in granular leukocytosis, leukaemoid reaction, granulocytic leukemia, multiple myeloma,

malaria, hypothyroidism. None of the cases had any diseases. The typical count of lobes of neutrophils, the characteristics pattern of nuclear chromatin and its familial incidence all supported the diagnosis of true Pelger-Huet anomaly.




Figure 4: The distribution of nuclear segments in the neutrophils in a normal patient, before treatment, untreated patient with megaloblastic anemia and after treatment vitamin B12

Table 3: Comparative incidence of Pelger- Huet anomaly

Region	Incidence	Authors
London	1:6000	Davidson (1961)
U.S.A	1:4758	Skendzel and Hoffman(1962)
Holland, Germany(1959)	1:4000	Ebbing
Berlin	1:1000	Nachtsheim(1950)
India(Western Madhya Pradesh) Tribal population	1:310	GehlotandMonga(1971)

Surprisingly, the prevalence and highest incidence of the Pelger- Huet anomaly of leucocytes i.e. 1:310 in the world has been observed in tribal population especially in Bhilala and Bhils scheduled tribes of Western Madhya Pradesh in India.

DISCUSSION AND CONCLUSION

Although the neutrophils in Pelger-Huet anomaly are morphologically different from the normal, they have been shown to behave normally in other respects. Thus they show normal phagocytic activity and have a normal survival in circulation. Whether the neutrophils showing the Pelger-Huet morphology show an increase in nuclear segmentation response to a megaloblastic form of hematopoiesis has not hitherto been described. By contrast, megaloblastic anemia of corresponding severity in a patient without the Pelger-Huet anomaly produced a decrease in lobes. Thus the Pelger Huet neutrophils respond in the usual manner during the megaloblastic process.

REFERENCE

1. Pelger, K.: Demonstratie van eepaarzeldzaamvoorkomend typen van bloedlichaampjes en bespreking der patienten. Nederl, tijdschr geneesk 72: 1178, 1928
2. Huet, G. J.; Familial anomaly of leucocytes. Nederl. tijdschr. Geneesk 75: 5956-5959, 1931
3. Davidson W. M. Lawler, S. D. and Ackerley, A. G. The Pelger-Huet anomaly, investigation of family, "A" Ann. Hum. Genet. 19:1-9, 1954
4. Davidson W.M. 1961 Inherited variation ion leucocytes. Br Med Bull 17,190
5. Carper, A.H and Hoffman. P.L. 1966. The intravascular survival of transfused canine PelgerHuet neutrophils and eosinophils. Blood 27, 739.
6. Gehlot G.S and Monga J.N. Prevalance of Pelger-Huet anomaly in adiwasi population in western Madhya Pradesh.
7. Skendzel, L. and Hoffman, G.1962. Pelger anomaly of leucocytes. AmJ Clin Pathol 37, 294
8. Bhola, V. and Monga, J.N. 1972. Incidence of Haemoglobinopathies amongst Adivasi population of Districts Dhar and Jhabua of Madhya Pradesh. (unpublished)
9. Dorr, A.D. and Maloney, W, C. 1959. Acquired pseudo Pelger-Huet anomaly of granulocytic leucocytes N Eng J Med 261,742.