

Morphometric study of radial artery

Nitin R Mudiraj^{1*}, Manisha R Dhobale²

¹Professor, ²Assistant Professor, Department of Anatomy, Bharati Vidyapeeth Deemed University, Medical College and Hospital, Sangli, Maharashtra, INDIA.

Email: dr.nitinmudiraj09@gmail.com

Abstract

Radial artery has been used in coronary artery bypass grafting, in forearm flap surgeries and in renal dialysis by making an autogenous fistula. In present study, ninety upper limbs from 45 formalin-fixed cadavers were dissected meticulously to expose the radial artery from its origin to its termination. The morphometric parameters like distance between interepicondylar line and bifurcation of brachial artery, length of radial artery and internal diameter of radial artery at various levels were measured. In cases of usual bifurcation of brachial artery, mean distance between interepicondylar line (IEL) and bifurcation of brachial artery on right side was 3.56 cm and on left side it was 3.49 cm and the mean length of radial artery on the right side was 26.73 cm and on left side it was 26.58 cm. Average distance of high bifurcation of brachial artery above the interepicondylar line was found to be 5.1 cm on the right side and 4.9 cm on the left side. The length of radial artery from its origin to the first dorsal interosseous space in the cases of high bifurcation of brachial artery was found to be in the range of 27.0 - 46.5 cm on the right side and 28.0 - 47.0 cm on the left side. The length of radial artery from its origin to the first dorsal interosseous space in the cases of high origin of radial artery was found to be in the range of 40.0 - 45.0 cm. The mean diameter of radial artery on right side was 2.35 mm and on left side it was 2.30 mm.

Keywords: morphometric, radial artery, interepicondylar line, diameter, length, coronary artery bypass graft.

*Address for Correspondence:

Dr. Nitin R Mudiraj, Professor, Department of Anatomy, Bharati Vidyapeeth Deemed University, Medical College and Hospital, Sangli. Zip code- 416414, Maharashtra, INDIA.

Email: dr.nitinmudiraj09@gmail.com

Received Date: 03/04/2015 Revised Date: 12/04/2015 Accepted Date: 19/04/2015

Access this article online

Quick Response Code:



Website:

www.statperson.com

DOI: 01 May 2015

INTRODUCTION

Radial artery is one of the terminal branches of the brachial artery. The radial artery usually appears to be the direct continuation of the brachial artery. It begins about 1cm distal to the bend of the elbow at the level of the neck of the radius and just medial to the tendon of biceps brachii. Then it descends along the lateral side of forearm to wrist, where it is palpable between flexor carpi radialis medially and the salient anterior border of the radius. The artery is accompanied by a pair of venae comitantes along its entire extent. The radial artery enters the hand between the two heads of first dorsal interosseous muscle and then

appears, in the palm, between the oblique and transverse heads of the adductor pollicis. At the base of fifth metacarpal it anastomoses with the deep branch of the ulnar artery, completing the deep palmar arch.^[1] The Radial artery currently regarded as a useful vascular site for coronary procedures alternative to femoral access due to superficial course that make it easily accessible and effectively compressed for haemostasis induction, early patient ambulation and increased post-operative comfort. Also it has a relative lack of local vascular complication associated with the femoral approach.^[2] The knowledge of the radial artery variation is useful as one can get confused with veins, which can lead to accidental injection of anaesthetic agent in the artery leading to distal necrosis of limb.^[3] It was found that even though radial artery can be used in a wide-ranging clinical application there is dearth of literature pertaining to the morphometric anatomy of radial artery in Indian subjects. Hence present study was done to contribute some of the morphometric features of radial artery to the literature.

MATERIALS AND METHODS

The upper limb of 45 cadavers which were embalmed using 10% formalin making it a total of 90 specimens

were used for this study. The study technique consisted of meticulous dissection and observation. In each cadaver, the upper limb was in abducted and laterally rotated position. An incision was made on the front of the arm from the tip of acromion process of the scapula up to the cubital fossa in the midline to expose the brachial artery and its venae comitantes. Then the incision was extended in the antecubital region along the medial border of biceps tendon and further extended up to the wrist. Skin and superficial fascia were reflected from the deep fascia by blunt dissection. The deep fascia including bicipital aponeurosis was incised vertically and biceps tendon retracted laterally to expose the contents of the cubital fossa. Brachial artery was exposed between the tendon of biceps and median nerve. The site of bifurcation of brachial artery was clearly exposed and the distance between the interepicondylar line of humerus and bifurcation of brachial artery was measured with the help of divider and measuring scale. After dividing the fascia of forearm from the cubital fossa up to the proximal margin of flexor retinaculum, the muscles exposed consisted of flexor group medially and extensor group laterally. Then the radial artery was traced distally from the bifurcation of brachial artery at the level of neck of the radius to the distal end of the radius. The length of the radial artery from its origin up to the first dorsal interosseous space was measured with the help of thread and scale. The internal diameter of the radial artery at its

origin, midway and at anatomical snuffbox (ASB) was measured with the help of divider and scale. Midway point is actually the midpoint of the length of radial artery. At each of these levels, diameter was measured at perpendicular points. The artery was cut and then spread out and its circumference was measured and the diameter was calculated using the formula i.e. $\text{circumference} = 2 \pi r$ where r = radius and diameter being $2r$. The average of all the 3 measurements at a level was calculated to arrive at the final diameter at a given level.

OBSERVATIONS AND RESULTS

Various parameters of radial artery were studied in 90 specimens belonging to 45 cadavers. Of these 45 cadavers, 3 were females. We classified specimens into 3 categories as-

- Showing bifurcation of brachial artery at usual site into radial artery and ulnar artery (78 specimens)
- Showing high bifurcation of brachial artery and hence showing high origin of radial artery (12 specimens)
- Showing high origin of radial artery but bifurcation of brachial artery at usual site into ulnar artery and common interosseous artery (3 specimens)

Table 1: Level of bifurcation of brachial artery from interepicondylar line (IEL) and number of cases

Range (cm)	Right	%	Left	%
2.0-3.0	11	28.22	10	25.64
3.1-4.0	16	41.02	23	58.98
4.1+	12	30.76	6	15.38
Total	39	100.00	39	100.00

Table 2: Distance between IEL and bifurcation of brachial artery at usual site

Side	No. of specimens	Mean (cm)	SD	Range (cm)
Right (RT)	39	3.56	0.70	2.0- 5.0
Left (LT)	39	3.49	0.62	2.1 -4.7

Table 3: Distance between the site of high origin of radial artery and interepicondylar line (cm)

Sr. No.	Right	Left
1	-	17.0
2	13.3	16.0

The distance between the site of high origin of radial artery and interepicondylar line was found to be in the range of 13.3 – 17.0 cm. However in these 3 specimens,

the bifurcation of brachial artery was found to be at the usual site (below the interepicondylar line) into common interosseous and ulnar arteries. (Table 3)

Table 4: In high origin of radial artery, distance between bifurcation of brachial artery and interepicondylar line (cm)

Sr. No.	RIGHT	LEFT
1	-	3.2 (below IEL)
2	3.0 (below IEL)	3.2 (below IEL)

Table 5: Distance between the site of high bifurcation of brachial artery and interepicondylar line (cm)

Sr. No	Right	Left
1	4.0	3.6
2	3.2	-
3	16.3	11.5
4	1.4	1.7
5	0.7	3.1
Mean	5.1	4.9

In 9 cases, there was high bifurcation of brachial artery and hence high origin of radial artery. The distance

between this high bifurcation of brachial artery and interepicondylar line is tabulated in table 5.

Table 6: Length of radial artery and number of cases in specimens of usual bifurcation of brachial artery

Range (cm)	Right	%	Left	%
23.1-26.0	15	38.47	16	41.02
26.1-29.0	22	56.41	19	48.72
29.1+	2	5.12	4	10.26
Total	39	100.00	39	100.00

Table 7: Length of radial artery (from its origin to first dorsal interosseous space) in case of usual bifurcation of brachial artery

Side	No of specimens	Mean (cm)	SD	Range(cm)
Right	39	26.73	1.57	23.5-30.5
Left	39	26.58	1.98	22.0-31.0

Table 8: Length of radial artery in cases of high origin and in high bifurcation of brachial artery

Sr. No.	RIGHT	LEFT
1	28.5	28.0
2	27.0	*45.0
3	46.5	47.0
4	27.5	29.0
5	31.5	29.0
6	*40.0	*40.5

*High origin of radial artery from brachial artery

The length of radial artery from its origin to the first dorsal interosseous space in the cases of high origin of radial artery was found to be in the range of 40.0 - 45.0 cm. The length of radial artery from its origin to the first

dorsal interosseous space in the cases of high bifurcation of brachial artery was found to be in the range of 27.0 - 46.5 cm on the right side and 28.0 – 47.0 cm on the left side (Table 8)

Table 9: Diameter of radial artery at its origin and number of cases

Range (mm)	Right	%	Left	%
1.5-2.4	23	51.12	21	46.67
2.5-3.4	18	40.00	5	11.11
3.5+	4	8.88	19	42.22
Total	45	100.00	45	100.00

Table 10: Diameter of radial artery at its origin (mm)

Side	No of specimens	Mean (mm)	SD	Range(mm)
Right	45	2.61	0.61	1.5-3.8
Left	45	2.59	0.64	1.5-4.2

Table 11: Diameter of radial artery at midway and number of cases

Range (mm)	Right	%	Left	%
0.9-1.8	15	33.33	16	35.55
1.9-2.8	16	35.55	18	40.00
2.9+	14	31.12	11	24.45
Total	45	100.00	45	100.00

Table 12: Diameter of radial artery at midway (mm)

Side	No. of specimens	Mean (mm)	SD	Range (mm)
Right	45	2.37	0.74	1.3-3.8
Left	45	2.24	0.74	0.9-3.9

Table 13: Diameter of radial artery at anatomical snuffbox (ASB) and number of cases

Range(mm)	Right	%	Left	%
1.0-1.9	25	55.55	21	46.66
2.0-2.9	13	28.89	19	42.22
3.0+	7	15.56	5	11.12
Total	45	100.00	45	100.00

Table 14: Diameter of radial artery at anatomical snuffbox (ASB) in mm

Side	No. of specimens	Mean (mm)	SD	Range (mm)
RIGHT	45	2.07	0.66	0.9-3.5
LEFT	45	2.09	0.64	1.0-3.5

Table number 10,12 and 14 show that, there is progressive reduction in diameter from the origin to its termination. Taking all the above values into consideration, the mean diameter of radial artery on right

side was found to be 2.35 mm and on left side it was found to be 2.30 mm and there was no statistically significant difference between the two sides.

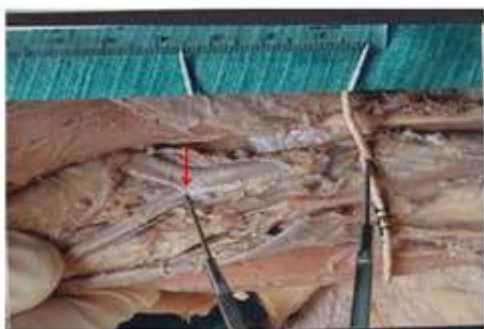


Figure 1: Showing the measurement of bifurcation of brachial artery arrow from the interpicodylar line (IEL)



Figure 2: Showing the measurement of length of radial artery from its origin to first dorsal interosseous space

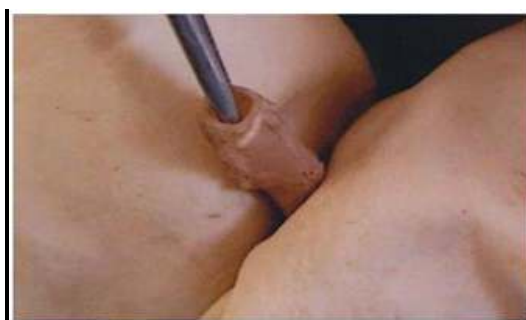

Figure 3: Showing measurement of internal of radial artery




Figure 4: Showing measurement of the circumference of the radial artery

DISCUSSION

Variations of the arterial patterns in the upper limb have been the subject of many anatomical studies due to their high incidence. However, some important aspects have until now remained confused or un-studied, due to the use of different terminologies and of different criteria for

classifying and or subclassifying them. According to Patnaik (2001) the average distance between the intercondylar line and bifurcation of brachial artery was 2.99 cm.⁴ Mullan (2003) studied the variation in the bifurcation of brachial artery in 30 Caucasian cadavers. The average level of bifurcation above the

interepicondylar line was 20.1cm and average level of bifurcation below the interepicondylar line was 2.75cm.⁵ McCormack (1953) reported the distance between the site of high origin of radial artery and intercondylar line of humerus in the range of 15-19.5cm.⁶ According to Acar (1991) mean length of the radial artery was 22.5 ± 1.2 cm.⁵ Patnaik stated that mean length of the radial artery was 26.29cm. He also measured the diameter of the radial artery in living persons during surgery after dilating the artery with papaverine using magnifying loupes and graduated ruler. He found the mean diameter of radial artery to be 2.7 ± 0.06 mm.⁷ Coronary Artery Bypass Graft (CABG) is the revascularisation surgery that requires harvesting of autologous graft. The graft vessel most frequently used is internal thoracic artery or great saphenous vein. Because of some reason if great saphenous vein or internal thoracic artery cannot be used, the radial artery may be used for CABG.⁸ Acar *et al* reported the superiority of radial artery over the internal thoracic artery as an autologous graft for CABG because of its length, more corresponding diameter to a large coronary artery and a decreased incidence of hypoperfusion syndrome as commonly seen with internal thoracic artery. It is technically easy to work with, is sufficiently long to reach any point on epicardial surface and its harvest is straightforward and quick.⁷

CONCLUSION

Knowledge of the vascular patterns, length and diameters of radial artery gained more importance in advanced

cardiac revascularization surgical techniques as well as in microsurgical techniques of reconstructive hand surgery.

REFERENCES

1. Williams PL, Bannister LH, Berry MM *et al*. Grey's Anatomy. In: Cardiovascular System. 38th ed. London Churchill Livingstone, 1999; 299.
2. A.Y. Nasr. The radial artery and its variation: anatomical study and clinical implication. *Folia morphol.* 2012; 71(4): 252-62.
3. Drizenko A, Maynou C, Mestdagh H, Bailleul JP. Variations of radial artery in man. *Surg Radiol Anat.* 2000; 22(5-6): 299-303.
4. Patnaik, VVG, Kalsey G, Singla, R K. Bifurcation of Axillary artery In Its 3rd Part -A case report. *J. Anat. Soc. India.* 2001; 50(2): 166-169.
5. Mullan, Geoffrey, Naeem PJ, Ellis H. Variation in the bifurcation of brachial artery in 30 Caucasian cadavers. *Clin. Anat.* 2003; 16(5): 461-465.
6. Mc Cormack LJ, Cauldwell EW, Anson BJ. Brachial and antebrachial arterial patterns; a study of 750 extremities. *Surg Gynecol Obstet.* 1953; 96: 43-54.
7. Acar C, Jebara VA, Portognese M, Fontaliran F, Devaniam P, Chchques JC, Meinger V, Carpenter A : Comparative anatomy and histology of the radial artery and the internal thoracic artery :implication for coronary artery bypass. *Surg. Radiol Diagnosis* 1991; 13: 283-288.
8. Barry MM, Foulon P, Touati G, Ledoux B, Sevestre H, Carmi M. Comparative histological and biometric study of the coronary, radial and left internal thoracic arteries. *Surg. Radiol Anat.* 2003; 25: 284-289.

Source of Support: None Declared
Conflict of Interest: None Declared