

A role of ultrasonography in right iliac fossa pain and avoidance of unnecessary removal of normal appendix

Sanjeeva Kumar Choudhary¹, Ved Rajan Arya^{2*}, Bhaskar Kumar³

¹Associate Professor, ²Assistant Professor, ³PG Student, Department of Surgery, M G M Medical College and L S K Hospital, Kishanganj, Bihar, INDIA.

Email: dr.kumarbhaskar@gmail.com

Abstract

Numerous diseases mimic appendicitis, and it is often difficult to rule it out on the basis of clinical presentation. Based on the clinical, laboratory and radiological findings can help in the diagnosis of acute appendicitis. A prospective, single centre based observational study carried out at our Rural Medical College. 100 patients were admitted with preliminary complains of pain Right iliac fossa. Clinical examination along with the laboratory and radiological findings was able to differentiate patients who came with pain Right iliac fossa but were having normal appendix from the patients who were actual cases of acute appendicitis. In patients with histologically confirmed acute appendicitis taking as the standard. The WBC count, Ultrasonography and CT Scan when combined with reliable clinical signs and symptoms is an excellent diagnostic marker of the disease is so that proper handling of the patient can be done and we can prevent unnecessary appendectomies in pain Right iliac fossa.

Keywords: ultrasonography, appendix.

*Address for Correspondence:

Dr. Ved Rajan Arya, Assistant Professor, Department of Surgery, M G M Medical College and L S K Hospital, Kishanganj, Bihar, INDIA.

Email: dr.kumarbhaskar@gmail.com

Received Date: 02/05/2015 Revised Date: 10/05/2015 Accepted Date: 14/05/2015

Access this article online

Quick Response Code:



Website:

www.statperson.com

DOI: 16 May 2015

INTRODUCTION

Acute appendicitis is still the most frequent cause of Right lower quadrant pain and the most common acute surgical condition of the abdomen. Acute appendicitis remains one of the most serious abdominal illnesses. It is a pathological condition that requires immediate surgical treatment. Its reported overall mortality rate is 0.3%, which rises considerably in cases of perforation (6.5%), older patients (5.5%) or neonates (80%)¹. Numerous diseases mimic appendicitis, and it is often difficult to rule it out on the basis of clinical presentation. The frequency of appendicitis and the high rates of negative

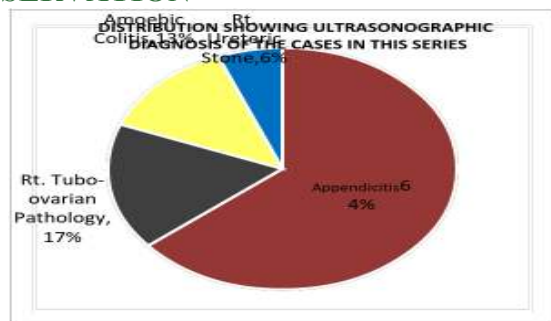
appendectomies, reported to be between 6% and 36%, have led to continuing efforts to develop new diagnostic methods that have the highest possible sensitivity and specificity in order to reduce the rate of negative appendectomies². Despite the multiple modern diagnostic tools that are available, diagnosis of acute appendicitis is still primarily done by history and physical examination. Additional diagnostic measures like temperature measurement, urinalysis and laboratory tests are routinely performed. Polymicrobial flora, predominantly, anaerobes, are usually found in an inflamed appendix. In recent studies, procalcitonin (PCT) has clearly been shown to be one of the most important biochemical indicators that closely correlate with the severity of the inflammatory host response to microbial infections³. It has been seen that the level of procalcitonin correlates with severity of inflammation⁴. One of the most practical scoring systems is the Alvarado scoring system which is based on history, physical examination, and some laboratory investigations that are convenient to apply⁵⁻⁷. Nevertheless, definite diagnosis can only be made after the operation and by histopathology examination of the collected specimens⁸. However ultrasonography remain

one of the most dependable and reliable investigation to diagnose Appendicitis.

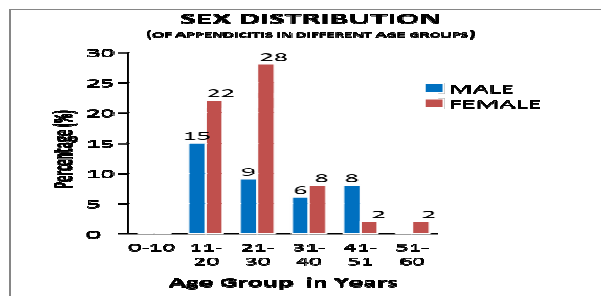
MATERIALS AND METHODS

The present study is a hospital based prospective observational study conducted in the “Department of Surgery, MGM Medical College and LSK Hospital”. The study is approved by the Institutional Ethics Committee of Hospital and informed consent has been taken up when the case were seen. A total of 100 patients were included in the study that were having pain right iliac fossa. Twenty eight patients were admitted with preliminary diagnosis of acute appendicitis. The study was done for a period of two years. All the patients were examined for signs and symptoms of disease on admission. A detailed history was taken and examination was done. Blood samples were collected. The investigations done on the patients were, body temperature, white blood cell (WBC) count, erythrocyte sedimentation rate (ESR), c reactive protein (CRP) levels, ultrasonography (USG) and computed tomography (CT) scan of abdomen pelvis (if required), depending solely on requirements. Emphasis was laid on WBC count, USG and clinical findings. Morphological investigation (histopathology) of appendix was also carried out.

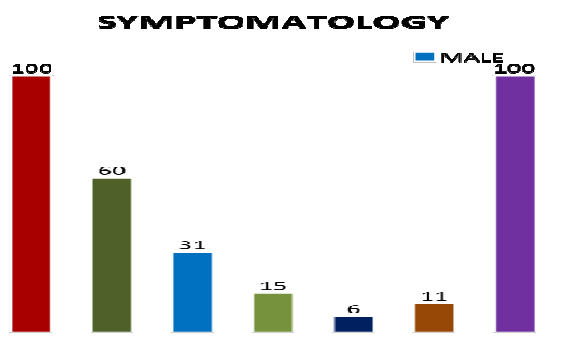
OBSERVATION



In this hospital based prospective observational study 100 cases who came to the emergency surgical ward and OPD with symptoms of pain right iliac fossa were admitted. Out of 100 cases only 64 cases were having appendicitis, 17 cases were tubo-ovarian pathology, 13 cases were having amoebic colitis and 6 cases were having right ureteric stone.



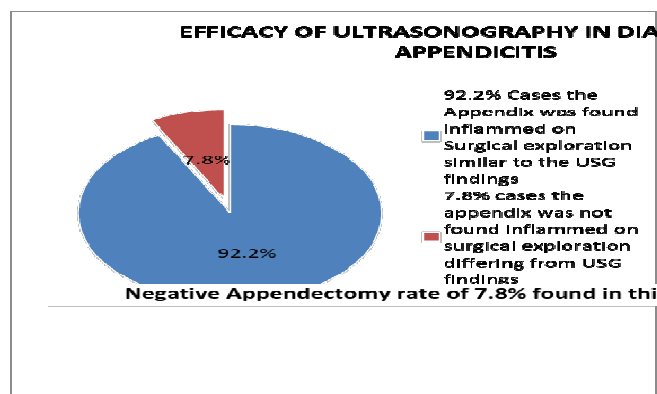
Out of the 64 cases of appendicitis 26 were male and 38 female showing a male to female ratio of 1:1.5. In males the highest incidence of appendicitis was encountered in the age group 11-20 and in females 21-30 yrs.



Pain was found to be the presenting symptom in every case in this series. Almost 60% cases presented with Nausea and vomiting. 31 cases presented with altered bowel habits. 15 cases presented with menstrual symptoms. 6 cases were having symptoms related to urinary symptoms. In present series all cases had tenderness in right iliac fossa in McBurney's point. 65% cases in this series presented with Leucocytosis with a predominant increase in neutrophil percentage, the others had total WBC range within normal limit.

DISCUSSION

In our study 65% of the cases in this series presented with leukocytosis with predominantly increase in the neutrophil percentage. Out of 100 cases ultrasonography diagnosed 64 cases to be having appendicitis. In the 64 cases of USG proven appendicitis had undergone appendectomy. Of these 59 cases were apparent surgically proven to be suffering from appendicitis, whereas 5 cases were not having a pathological appendix on surgical exploration. Hence producing a negative appendectomy rate of 7.8%. According to some studies ultrasound has a sensitivity ranging from 49 to 90 %, a specificity ranging from 47 to 100 %, a positive predictive value of 84 to 93 %, and an overall accuracy of 72 to 94 % for the diagnosis of Acute appendicitis⁸⁻¹².



CONCLUSIONS

Acute appendicitis may be one of the most if not common cause of acute right iliac fossa pain. But other pathologies causing right iliac fossa pain is almost 35-40% of the number of cases of right iliac fossa pain. This study was based on the use of ultrasonography to diagnose right iliac fossa pain and hence reduce the rate of negative appendectomies and it appear to justify as the rate of removal of appendix drastically reduced by the increasing use of ultrasonography in diagnosis of right iliac fossa pain. Ultrasonography supported by clinical and laboratory findings has almost 0% false negative results but account to 6-7% false positive results.

REFERENCES

1. Blomqvist PG, Andersson RE, Granath F *et al* (2001) Mortality after appendectomy in Sweden, 1987–1996. *Ann Surg* 233:455–460
2. Schwarz A, Bolke E, Peiper M *et al* (2007) Inflammatory peritoneal reaction after perforated appendicitis: continuous peritoneal lavage versus nonlavage. *Eur J Med Res* 12:200–205
3. Carrol ED, Thomson AP, Hart CA (2002) Procalcitonin as a marker of sepsis. *Int J Antimicrob Agents* 20:1–9
4. Kouame DB, Garrigue MA, Lardy H *et al* (2005) Is procalcitonin able to help in paediatric appendicitis diagnosis? *Ann Chir* 130 (3) :169–174
5. Alvarado A. A practical score for the early diagnosis of acute appendicitis. *Ann Emerg Med* 1986; 15(5):557-64.
6. Soomro AG, Siddiqui FG, Abro AH, Abro S, Shaikh NA, Memon AS. Diagnostic accuracy of Alvarado scoring system in acute appendicitis. *J Liaquat Univ Med Health Sci* 2008;7:93-6.
7. Memon ZA, Irfan S, Fatima K, Iqbal MS, Sami W. Acute appendicitis: Diagnostic accuracy of Alvarado scoring system. *Asian J Surg* 2013; 36(4):144-9.
8. Pinto F, Pinto A, Russo A, Coppolino F, Bracale R, Fonio P, *et al*. Accuracy of ultrasonography in the diagnosis of acute appendicitis in adult patients: review of the literature. *Crit Ultrasound J* 2013; 5 Suppl 1:S2.
9. Birnbaum BA, Jeffrey RB Jr. CT and sonographic evaluation of acute right lower quadrant abdominal pain. *AJR Am J Roentgenol* 1998; 170(2):361-71.
10. Jahn H, Mathiesen FK, Neckelmann K, Hovendal CP, Bellstrøm T, Gottrup F. Comparison of clinical judgment and diagnostic ultrasonography in the diagnosis of acute appendicitis: experience with a score-aided diagnosis. *Eur J Surg* 1997; 163(6):433-43.
11. Birnbaum BA, Wilson SR. Appendicitis at the millennium. *Radiology* 2000; 215(2):337-48.
12. Paulson EK, Kalady MF, Pappas TN. Clinical practice. Suspected appendicitis. *N Engl J Med* 2003; 348(3):236-42.

Source of Support: None Declared
Conflict of Interest: None Declared