Case Report

Oncocytic papillary thyroid carcinoma - A rare case report

Madasamy Balamurugan[1*], C P Luck[2], V Aruna Padmavathy[3], R Ragavi[4]

[1]Professor and HOD, [2]Associate Professor, [3]Assistant Professor, [4]Student, Department of Pathology, Tagore Medical College and Hospital, Chennai–600127, Tamil Nadu, INDIA.
Email: balamuruganpath@tagoremch.com, balamurugan.pathology@gmail.com, cpluuckkamal@gmail.com, aruna.paddu@gmail.com

Abstract

Oncocytic variant of papillary thyroid carcinoma (PTC) is a rare subtype of thyroid tumors. It can show considerable architectural and cellular variations and its biological behavior is not well documented. The tumor cells of Oncocytic variant of PTC characteristically have eosinophilic, granular cytoplasm due to mitochondrial content. But nuclear features are typical of PTC which is optically clear with some time showing grooves. Due to these features it can present considerable diagnostic difficulty particularly in Fine Needle Aspiration Cytology (FNAC). We present this case of Oncocytic variant of PTC for its rarity and diagnostic difficulty.

Keywords: Fine needle aspiration cytology, oncocytic neoplasms, oncocytic variant of papillary thyroid carcinoma, papillary carcinoma thyroid.

***Address for Correspondence:**
Dr. Madasamy Balamurugan, Professor and HOD, Department of Pathology, Tagore Medical College and Hospital, Chennai–600127, Tamil Nadu, INDIA.
Email: balamuruganpath@tagoremch.com
Received Date: 02/08/2015 Revised Date: 27/08/2015 Accepted Date: 10/09/2015

Access this article online	
Quick Response Code:	Website: www.statperson.com
	DOI: 11 September 2015

INTRODUCTION

Oncocytic variant of papillary thyroidcarcinoma (PTC) is a rare subtype of papillary thyroid carcinoma. Its biological behavior and pathological features are not well documented. The patterns of growth vary from papillary, follicular, solid and can overlap considerably. It can be capsulated or invade the normal thyroid tissue. The tumor cells of oncocytic variant of PTC have a distinct oxyphilic/oncocytic, Hurthle cell like cytoplasm due to the abundant mitochondrial content. However they have the characteristic nuclear features pertaining to papillary carcinoma of thyroid. The nuclei are optically clear with grooves and indistinct nucleoli**.** It contributes up to 10% of all papillary carcinomas of thyroid. It is seen 80% in women, aged between 34-86 yrs. This variant has also been termed as Hurthle cell variant or oxyphilic variant. Most of the patients are euthyroid and present with local compression symptoms like dysphonia and dysphagia. Secondary changes like hemorrhage and infarction are common[1]. BRAF mutation is seen in many patients with oncocytic variant of PTC[2]. Here we report a rare case of oncocytic variant of papillary thyroid carcinoma in a 35 year old female patient who had undergone total thyroidectomy. Initially the Fine Needle Aspiration Cytology (FNAC) was inconclusive and diagnosed as nodular colloid goiter with Hurthle cell changes. We diagnosed this case as oncocytic variant of PTC on histopathological basis. This case is presented for its rarity and diagnostic difficulty of oncocytic variant of PTC.

CASE REPORT

A 35 year old female patient was admitted in our hospital with complaints of swelling in the neck and difficulty in swallowing for the past two years. A firm single swelling measuring 7x6cm over right lobe of thyroid was found moving with deglutition. The surface was smooth. Pulsation was seen lateral to the right lobe, and lower border of the thyroid was clearly felt. Routine preoperative investigations including Thyroid function test were normal. Fine needle aspiration revealed only Hurthle cells and follicular cells. A diagnosis of Nodular colloid goiter with Hurthle cell change was suggested and

How to site this article: Madasamy Balamurugan, C P Luck, V Aruna Padmavathy, R Ragavi. A study of chronic allergic rhinitis in rural area and its management by cryosurgery. *International Journal of Recent Trends in Science and Technology.* September 2015; 16(2): 371-373 http://www.statperson.com (accessed 14 September 2015).

histopathological examination was advocated due to suspicious nuclear grooves in tumor cells and on clinical suspicion. Total thyroidectomy was done with no post-operative complications.

Gross examination

The thyroid was measuring 8x6cm with a large, grey white nodule on the right lobe. The cut surface showed the large nodule measures 3.5cm in diameter with dominant cystic change involving half of the nodule. The other half of the nodule appears pale white in color. Rest of the right lobe showed compressed pale brown thyroid parenchyma with mild nodularity. The isthmus appeared apparently normal and the left lobe showed a tiny whitish nodule measuring 0.5cm in diameter resembling the color of the dominant nodule (Figure 1).

Microscopic examination

Section showed a tumor separated from the compressed native thyroid tissue (Figure 2).The neoplasm showed abundant solid areas (Figure 3) composed of large cells with pale eosinophilic granular cytoplasm (Figure 5) and clear vesicular nuclei. Nuclei of the tumor cells were optically clear (Orphan Anne eye / Ground glass) (Figure 4)[3]. Nuclei were larger, oval and often overlap one another. Close examination of nuclei often revealed nuclear grooves. Few foci of papillary frondswere seen with fibrovascular core (Figure 6) lined by similar cells. The background shows few follicle formation (Figure 7), thick colloid and areas of hyalinization. The tiny nodule on the left lobe also showed tumor with papillary fronds. The rest of the thyroid showed changes consistent with nodular colloid goiter.

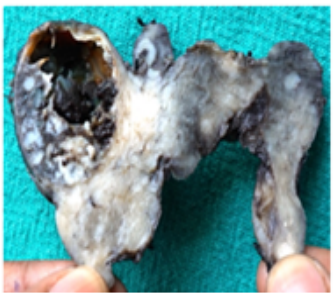

Figure 1

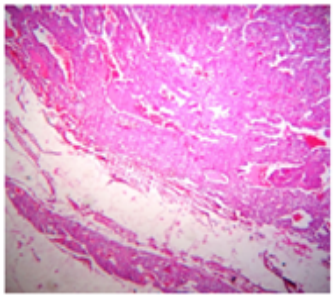

Figure 2

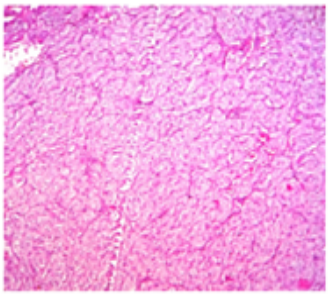

Figure 3

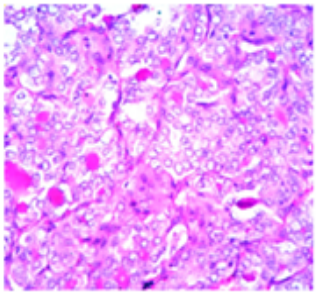

Figure 4

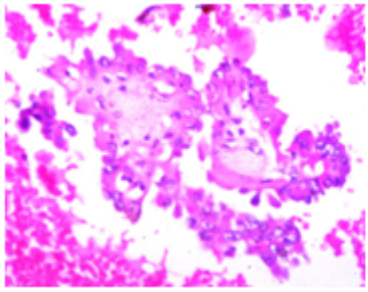

Figure 5

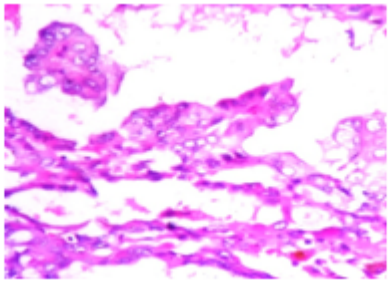

Figure 6

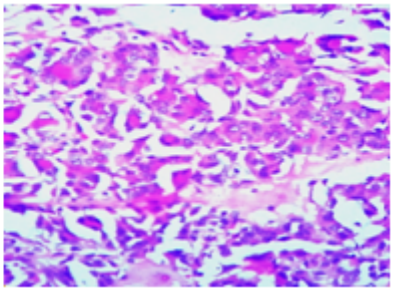

Figure 7

Legend

Figure 1: Thyroid showing cystic nodule with grey white areas.
Figure 2: Tumor separate from the normal thyroid tissue.
Figure 3: Solid area of the tumor.
Figure 4: Tumor cells with clear 'Orphan Anne eye' nuclei.
Figure 5: Tumor cells with eosinophilic granular cytoplasm in a papillary process.
Figure 6: Papillary fragment with a firbovascular core.
Figure 7: Tumor cells with follicle formation with thick colloid.

DISCUSSION

Oncocytic variant of PTC is a rare malignancy that presents diagnostic difficulties. It has variations in architecture like papillary, follicular, solid, cystic and histological variations like Hurthle cell change, hyalinization, colloid formation[1]. These variations along with only occasional papillary processes are the main cause of diagnostic difficulty in FNAC. Esther Diana Rossi *et al*. has reported 3 cases of false negative oncocytic variant of PTC among 150 cases of oncocytic neoplasms in FNAC[4]. Renshaw AA has reported much higher error as he could diagnose only 3 oncocytic variant of PTCs among 18[5]. Unless we sample the papillary area

while doing FNAC, smears will show only Hurthle cells and others. When few papillary foci are present the chances of missing the diagnosis in FNAC is more. Diagnosis only on the nuclear features in FNAC is not advisable since it can lead to false positive results. In our case because of the nuclear features and clinical suspicion we suggested histopathological examination. Histopathologically the diagnosis was simple since there were papillary processes with fibrovascular core along with the classical nuclear features[6]. Our case also showed a nodule of tumor away from the primary within thyroid in the left lobe which makes it metachronous. Oncocytic variant of PTC is in many instances associated with autoimmune disorders like Hashimoto's thyroiditis[1,7]. Sobrinho-simões M A in an ultrastructural study has even suggested that the granular cytoplasm of Oncotytic change in Oncocytic variant of PTC could be due to accumulation of intermediate filaments rather than mitochondria[8]. Accurate diagnosis is mandatory in case of Oncocytic variant of PTC since it affects the treatment and prognosis. Application of strict histological criteria is therefore necessary to distinguish these lesions from the other primary thyroid Oncocytic neoplasms that are characterized by similar oncocytic cytoplasmic features[3].

REFERENCES

1. Berho, Mariana, Saul Suster: The oncocytic variant of papillary carcinoma of the thyroid: A clinicopathologic study of 15 cases: Hum Pathol, 1997 January; 28(1):47 – 53.
2. V´ıtor Trovisco, Ines Vieira de Castro, Paula Soares, Valdemar Maximo, Paula Silva, Joao Magalh ˜aes, Alexander Abrosimov, Xavier Matias Guiu and Manuel Sobrinho-Simoes: BRAF mutations are associated with some histological types of papillary thyroid carcinoma: J Pathol, 2004 February; 202: 247–51.
3. Rogelio Gonzalez-Gonzalez, Ronell Bologna-Molina, Ramón Gil Carreon-Burciaga, Marcelo Gómezpalacio-Gastelum, Nelly Molina-Frechero, and Sirced Salazar-Rodríguez: Papillary Thyroid Carcinoma: Differential Diagnosis and Prognostic Values of Its Different Variants: Review of the Literature: International Scholarly Research Notices Oncology. 2011; 915925(9)
4. Esther Diana Rossi, Maurizio Martini , Patrizia Straccia, Marco Raffaelli, Ilaria Pennacchia, Eleonora Marrucci, Celestino Pio Lombardi, Alfredo Pontecorvi and Guido Fadda: The cytologic category of oncocytic (Hurthle) cell neoplasm mostly includes low-risk lesions at histology: an institutional experience: Eur J Endocrinol, 2013; 169: 649–655.
5. Renshaw AA: Fine needle aspirations of papillary carcinoma with oncocytic features. An expanded cytologic and histologic profile: Cancer Cytopathology, 2011; 119: 247–253.
6. Asa S L: My approach to oncocytic tumours of the thyroid: J ClinPathol. 2004 Mar; 57(3): 225–32.
7. Lee J, Hasteh F: Oncocytic variant of papillary thyroid carcinoma associated with Hashimoto's thyroiditis: a case report and review of the literature: DiagnCytopathol. 2009 Aug; 37(8):600 -6
8. M. A. Sobrinho-simões, J. M. Nesland, R. Holm, M. C. Sambade and J. V. Johannessen: Hürthle Cell and Mitochondrion-Rich Papillary Carcinomas of the Thyroid Gland: An Ultrastructural and Immunocytochemical Study: Ultrastruc Pathol. 1985; 8(2-3), 131-42.

Source of Support: None Declared
Conflict of Interest: None Declared