Case Report

Leri's diseases – A rare mesenchymal sclerosing bone dysplasia of right femoral neck

Ankit Jain[1*], Ishita Gupta[2], Hemant Kumar Mishra[3], A P Verma[4]

{[1]IIIrd Resident, [3]Professor and Head, [4]Professor, Department of Radiodiagnosis} {[2]IIIrd Resident, Department of Pathology}
Mahatma Gandhi medical college, Riico industrial area, sitapura, jaipur -302022, Rajasthan, INDIA.
Email: ankitj06m5209@gmail.com

Abstract

Introduction: Melorheostosis (synonyms: candle bone disease, melting wax syndrome, Leri disease) is a rare chronic bone disorder, first described in 1922 by Leri and Joanny. Men and women are equally affected, and no hereditary predilections have been discovered. Onset is insidious, and most common symptom is pain. Most common part of bone is diaphysis of the long bone of lower limb rarely the axial skeleton. Classical radiological appearance of 'flowing hyperostosis' resembles hardened wax that has dripped down the side of a candle. Here we described a case of Melorheostosis with characteristic clinical and imaging findings – a twenty five year old male presented to dept of orthopaedic; with complain of pain in the right leg and hip region which aggravated on vigorous exercise. Plain radiograph and CT shows hyperostotic areas with undulating irregular margin with evidence of irregular cortical thickening along the long axis of neck of right femur which are said to resemble the melting wax dripping down the side of a candle and pathology to confirm the diagnosis.

Keywords: Melorheostosis, Hyperostotic, Candle wax.

[*]**Address for Correspondence:**
Dr. Ankit Jain, 52/153, V T Road, Mansarovar, Jaipur, Rajasthan - 302020
Email: ankitj06m5209@gmail.com
Received Date: 28/05/2016 Revised Date: 02/07/2016 Accepted Date: 07/09/2016

Access this article online	
Quick Response Code:	Website: www.statperson.com
	DOI: 11 October 2016

INTRODUCTION

Melorheostosis, also known as Leri's disease and first reported by Leri and Joanny in 1922[1], is a rare, nonhereditary, and benign sclerosing mesenchymal dysplasia. The age of presentation is variable; however, in most of the cases, it manifests by 20 years of age. Men and women are equally affected, and no hereditary features have been discovered. Most common symptom is pain and onset of disease is insidious[2]. It may also present with limb-length discrepancy, joint stiffness, progressive deformity, ossification in adjacent soft tissues[3]. The exact cause of disease still remains unclear. This bony dysplasia has a classical imaging appearance and is characterized by irregular and wavy hyperostosis also referred to as "flowing candle Wax" appearance. Appendicular skeleton is more commonly involved as compared to axial skeleton[3,4]. Most common part of bone is diaphysis of the long bone of lower limb. The majority of cases described in the literature suggest that involvement of the lower extremity is more common.

CASE REPORT

A 25 year old male presented to dept of orthopaedic, with complain of dull and aching pain in the right thigh i.e. from hip to knee region since 5-6 years which is insidious in onset and progressive in nature. Pain aggravated on vigorous exercise. No relevant family history or history of trauma. No history of fever/ DM/ HTN/ TB/trauma.

Physical and Clinical Examination

General and Systemic examination are Normal. Musculoskeletal examination shows Localized tenderness, Joint stiffness, Slight limb shortening and restriction of movement. Laboratory Investigations, i.e. Hematological examination are normal. Sr.Calcium – Normal and *HLA B27 is negative.*

How to site this article: Ankit Jain, Ishita Gupta, Hemant Kumar Mishra, A P Verma. Leri's diseases – A rare mesenchymal sclerosing bone dysplasia of right femoral neck. *International Journal of Recent Trends in Science and Technology*. October 2016; 20(3): 355-357. http://www.statperson.com (accessed 16 October 2016).

Radiological Investigations

Plain radiograph of right hip and femur shows Hyperostotic areas with undulating irregular margin seen along the long axis of neck of right femur. Also evidence of irregular cortical thickening is seen. There is clear demarcation seen between normal and affected bone. Computed tomography scan of right femur shows multiple dense, undulating irregular areas of sclerosis/hyperostosis in right femur involving neck and proximal 2/3rd shaft with evidence of thickening of cortex along lateral margin. No evidence of cortical breach. Soft tissue calcification is also seen adjacent to tip of greater trochanter. Plain radiograph and Computed tomography reveal the lesions which are said to be resemble the

MELTING WAX DRIPPING DOWN THE SIDE OF A CANDLE

Also clear demarcation between normal and abnormal bone is made. *MRI of Pelvis and Both Hip Joints* shows well defined geographical areas of hypointensities on T1W, T2W and STIR with blooming on GRE seen in neck, greater and lesser trochanter as well as proximal part of shaft of right femur. Normal signal intensity is seen on left side hip joint. Imaging findings are in favor of dense sclerotic lesions involving right head, neck, greater and lesser trochanter as well as proximal part of shaft of right femur. Histopathological examination is done and shows supportive results.

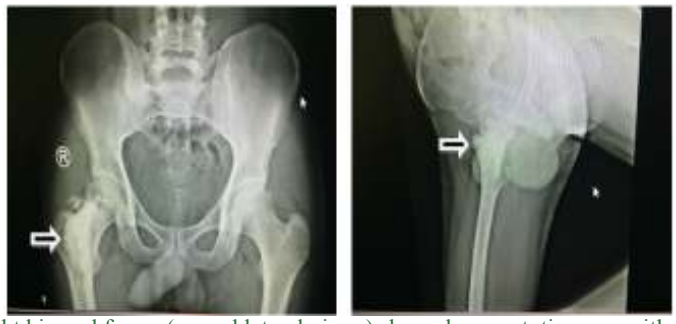

Figure 1: Plain radiograph of right hip and femur (ap and lateral views) shows hyperostotic areas with undulating irregular margin seen along the long axis of neck of right femur. Also evidence of irregular cortical thickening is seen

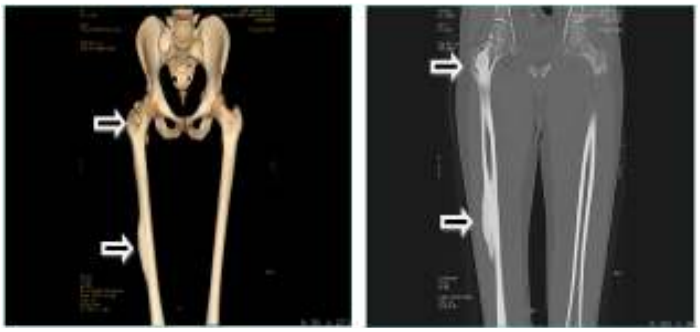

Figure 2: computed tomography scan of right femur (volume rendering and coronal image) shows multiple dense, undulating irregular areas of sclerosis/hyperostosis in right femur involving neck and proximal 2/3rd shaft with evidence of thickening of cortex along lateral margin. No evidence of cortical breach. Soft tissue calcification is also seen adjacent to tip of greater trochanter

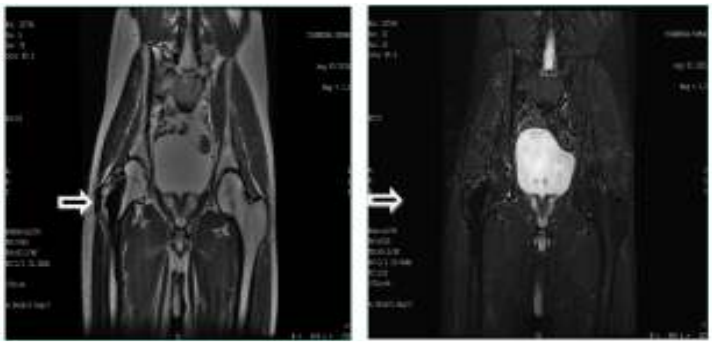

Figure 3: MRI of pelvis and both hip joints (t2w and stir coronal images) shows well defined geographical areas of hypointensities on t2w and stir seen in neck, greater and lesser trochanter as well as proximal part of shaft of right femur. normal signal intensity is seen on left side hip joint.

DISCUSSION

Melorheostosis is a rare, nonhereditary and benign mixed sclerosing mesenchymal dysplasia with disturbance of both intramembranous (predominantly) and endochondral ossification. It is also known as Leri's disease as first reported by Leri and Joanny in 1922 [1].The word melorheostosis is derived from the Greek words "melos" which means limb and "rhein" which means flow [5]. It has an incidence of 0.9 per million with no sex predilection. This rare sclerosing dysplasia has a variable age of presentation, ranging from 2 to 64 years. However, majority of the patients present by 20 years of age[6]. Clinical manifestations of melorheostosis are variable, ranging from chronic pain and stiffness to contracture and deformity of the involved limb. Melorheostosis may involve only one bone (monostotic), one limb (monomelic), or multiple bones (polyostotic). It is almost always unilateral, with only a few cases of bilateral involvement reported. The lower extremity is twice more commonly affected than the upper extremity, and the disease rarely involves the spine, skull, or facial bones. The etiology of Melorheostosis remains uncertain; however, a widely accepted theory attributes the disease to segmental sensory nerve insult (sclerotomal distribution), caused by a loss-of-function mutation of the LEMD3 gene, leading to bone scarring along its distribution[8]. Diagnosis of Melorheostosis is usually made radio graphically. Five patterns have been described

- Classic
- Osteoma like
- Myositis Ossificans like
- Osteopathia Striata like
- Mixed

The classic radiographic appearance is that of undulating irregular hyperostotic cortical changes along the long axis of bones, which are said to resemble melting wax dripping down the side of a candle. Not infrequently features of melorheostosis, osteopathia striata and osteopoikilosis may co-exist in so-called overlap syndromes. Computed tomography also reveals the lesions with clear demarcation between normal and abnormal tissue. Magnetic resonance imaging (MRI) reveals bone and soft tissue lesions as area of low signal intensity in all sequences [3]. Radionuclide bone scanning is also helpful in distinguish a focus of Melorheostosis from other lesions. In Melorheostosis, focal increased uptake is seen due to increased osteoblastic activity, local hyperaemia and immature collagen. Complications usually encountered are associated soft tissue lesions and cutaneous lesions, Vascular malformations, Neurofibromatosis, Tuberous sclerosis, Hemangioma, Muscle contractures and Scoliosis etc.

CONCLUSION

Melorheostosis is a rare, benign, and disabling condition. Involvement of axial skeleton is rare and coexistence of two bony dysplasias in one patient is even rarer. Knowledge of classical radiological findings and its pattern of involvement can prevent an unwarranted biopsy in these patients.

REFERENCE

1. Leri A, Joanny J. Une affection non décrite des os hyperostose "en coulée" sur toute la longeur d'un member ou "melorhéostose." Bull Mem Soc Med Hosp Paris.1922;46:1141–1145.
2. Biaou O, Avimadje M, Guira O, Adjagba A, Zannou M, Hauzeur JP. Melorheostosis with bilateral involvement in a black African patient. Joint Bone Spine. 2004; 71:70–72.
3. Greenspan A, Azouz EM. Bone dysplasia series: melorheostosis: review and update. Can Assoc Radiol J. 1999; 50:324–330.
4. Freyschmidt J.: Melorheostosis: a review of 23 cases. Eur Radiol 2001; 11: 474–9
5. Bansal A. The dripping candle wax sign. Radiology 2008; 246:638–40.
6. Resnick D. Diagnosis of bone and joint disorders. 3rd ed, Vol. 6.Philadelphia, PA: WB Saunders; 1995. p. 4410–3.
7. Zeiller SC, Vaccaro AR, Wimberley DW, Albert TJ, Harrop JS, Hilibrand AS. Severe myelopathy resulting from melorheostosis of the cervicothoracic spine: a case report. J Bone Joint Surg Am. 2005; 87:2759–2762.
8. Hellemans J, Preobrazhenska O, Willaert A, Debeer P, Verdonk PC, Costa T, et al. Loss-of-function mutations in LEMD3 result in osteopoikilosis, Buschke-Ollendorff syndrome and melorheostosis. Nat Genet. 2004; 36:1213–1218.

Source of Support: None Declared

Conflict of Interest: None Declared

How to site this article: Ankit Jain, Ishita Gupta, Hemant Kumar Mishra, A P Verma. Leri's diseases – A rare mesenchymal sclerosing bone dysplasia of right femoral neck. *International Journal of Recent Trends in Science and Technology*. October 2016; 20(3): 355-357. http://www.statperson.com (accessed 16 October 2016).