

# Auto immune pancreatitis - A case report

Remya Baburaj\*, Prabhu Radhan, Rajoo Ramachandran, Subramanian Ilanchezhian  
Praveen Kumar

Department of Radiology, Sri Ramachandra Medical College, Porur, Chennai - 600116

Email: [docradhan@yahoo.com](mailto:docradhan@yahoo.com)

## Abstract

It is a type of chronic pancreatitis characterized by a heterogeneous autoimmune inflammatory process associated with fibrosis of the pancreas causes organ dysfunction. There are three recognized radiological patterns of autoimmune pancreatitis: diffuse, focal, and multifocal. Diffuse disease is the most common type, with a diffusely edematous sausage-like appearing pancreas with well demarcated sharp margin and absence of the surface undulations. Focal disease is less common and manifests as a focal mass mimic pancreatic malignancy. We had a 52 year old male with history of epigastric pain and fever for a duration of 2 weeks referred to our department for MRI abdomen with contrast. The MRI of the patient revealed diffuse form of Autoimmune pancreatitis which will be discussed in detail.

**Keywords:** Auto immune pancreatitis.

## \*Address for Correspondence:

Dr. Remya Baburaj, Department of Radiology, Sri Ramachandra Medical College, Porur, Chennai - 600116

Email: [docradhan@yahoo.com](mailto:docradhan@yahoo.com)

Received Date: 14/11/2016 Revised Date: 06/12/2016 Accepted Date: 10/01/2017

## Access this article online

Quick Response Code:



Website:

[www.statperson.com](http://www.statperson.com)

DOI: 01 February  
2017

imaging, histologic pattern, serologic findings and extra pancreatic involvement (biliary, renal and retroperitoneum involvement). Some systems also take into account the response to cortico steroid therapy. Asian 2008 AIP diagnostic criteria is one of the accepted systems as mentioned below.

## DIAGNOSTIC CRITERIA FOR AUTOIMMUNE PANCREATITIS.[4]

Criteria I	Enlargement of the gland (may be diffuse/segmental/focal) +/- hypo-attenuating rim (halo)
	Pancreatic duct narrowing (may be diffuse/segmental/focal) +/- stenosis of the common bile duct
Criteria II	Elevated serum IgG or IgG4
Criteria III:	Detectable autoantibodies (ANA, RF)
	Lymphoplasmacytic infiltration (IgG4 positive) with fibrosis

## INTRODUCTION

It is a type of chronic pancreatitis characterized by a heterogeneous autoimmune inflammatory process associated with fibrosis of the pancreas causes organ dysfunction. It divided into two categories<sup>1</sup>. Type 1 is the most common type and is mainly associated with hyperimmunoglobulin G4, anti-nuclear antibody, anti-smooth muscle antibody, anti-lactoferrin antibody, and anti-carbonic anhydrase antibody. Type 2 is not associated with either specific autoantibodies or extra-pancreatic manifestations. There are three recognized patterns of autoimmune pancreatitis: diffuse, focal, and multifocal<sup>2</sup>. Diffuse disease is the most common type, with a diffusely edematous sausage-like appearing pancreas. In comparison to diffuse pattern, focal disease is less common and manifests as a focal mass, often with involvement of the pancreatic head. There are several established diagnostic criteria systems for auto immune pancreatitis in literature. These are mainly based on

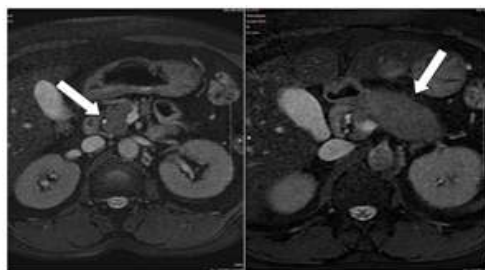
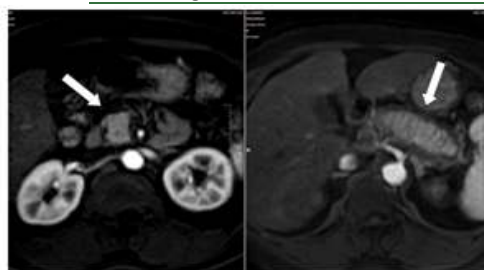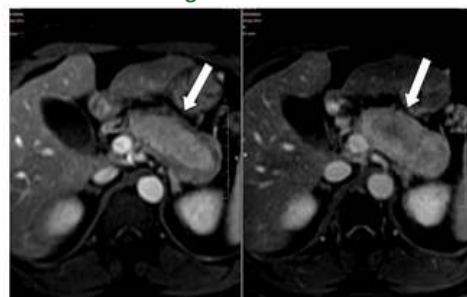
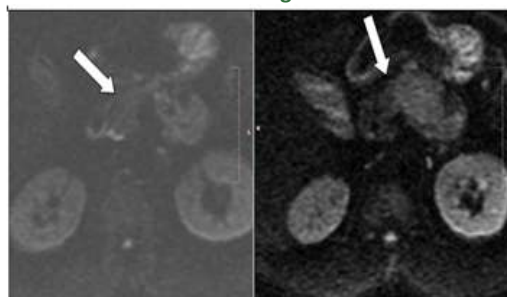
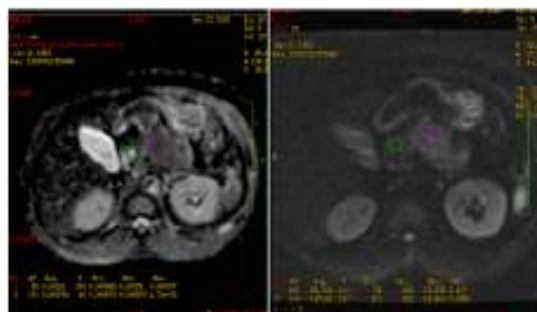
## CASE REPORT

A 52 year old male referred with history of epigastric pain and fever for duration of 2 weeks. There was no evidence of fever, diarrhea, constipation, ascites, hematemesis, lymphadenopathy, hepatosplenomegaly, or weight loss. Routine laboratory findings revealed increased liver function test. Pancreatic enzymes and Ca 19.9 markers were found to be normal. Chromograffin A level were found to be elevated (427 U/l). MRCP revealed diffuse enlargement of the body and the tail of pancreas with loss of normal surface undulations, abrupt blunt end to the tail giving a featureless sausage-shaped appearance.

**Table 1:** Laboratory findings

Blood index	Case	Normal range (u/L)
Lymphocytes	21.5	
Monocytes	6.2	
RBC	4.06	
FBS	121	70-110
Cholestrol	193	<200
LDL	133	<100
HDL	46	35-60
Cr	0.7	0.9 - 1.30
SGOT	36	<35

SGPT	163	<41
ALP	119	45-129
Total bilirubin	0.27	0.1 - 1.0
Direct bilirubin	0.16	0.0 - 0.30
Na	140	134-144
Chloride	100	96-108
K	4.6	3.50 - 5.00
Ca 19.9	7.42	0 - 39
Amylase	22	23 - 85
Lipase	50	0 - 160
Chromograffin A	427	<98.1

**Figure 1:****Figure 2:****Figure 3:****Figure 4:****Figure 5:**

**Figure 1:** Selected Ax. 2D FIESTA section reveals a normal appearing uncinus process and head region with diffuse enlargement of the body and the tail of pancreas with loss of normal surface undulations, abrupt blunt end to the tail giving a featureless sausage-shaped appearance

**Figure 2:** Selected Post contrast Ax LAVA (arterial phase) section depicts normal enhancing pancreatic parenchyma in the uncinus process, head and central portion of the body, tail regions. There is evidence of non enhancing peri-pancreatic rim noted in the body and tail regions

**Figure 3:** Selected Post contrast Ax LAVA (venous and delayed phases) section reveals normal enhancing pancreatic parenchyma and non enhancing peri pancreatic rim in the body and tail regions. On delayed images there is washout of the above mentioned region with delayed enhancement of the peri pancreatic rim suggesting its sclerosing component may represent capsule rim sign

**Figure 4:** Selected diffusion weighted images depicts a sharp demarcation between the normal uncinus process and head region and increased DWI signal on the body and tail regions

**Figure 5:** Selected ADC maps shows normal ADC values ( $16.1 \times 10^{-3}$ ) in the head and uncinus process and reduced ADC values ( $0.754 \times 10^{-3}$ ) in the body and tail region.

## DISCUSSION

Autoimmune pancreatitis can be diagnosed according to the following criteria:

1. Narrowing of the pancreatic duct with segmental or diffused irregularity and localized or diffused pancreatic enlargement observed in imaging modalities;
2. Increase in serum IgG4 levels and the presence of autoantibodies such as antinuclear antibody and rheumatoid factor (RF); and
3. Intralobular fibrosis, plasma cell and lymphocytic infiltration around the pancreatic ducts and local lymph node enlargement. Autoimmune pancreatitis is defined as the presence of criterion 1 with either criterion 2 or 3.

However, the most recent criteria for diagnosis of autoimmune pancreatitis has changed as follows:

- a. Imaging: diffused pancreas enlargement, segmental or diffused irregular narrowing of the main pancreatic duct.
- b. Laboratory findings: increased IgG4, presence of autoantibodies.
- c. Histopathologic findings: lymphoplasmacytic infiltration and fibrosis.
- d. Accompanied by other autoimmune diseases.

Auto immune pancreatitis is more common in males, presenting with complaints of diffuse abdominal or epigastric pain. Patients may present with complaints of obstructive jaundice. Type 1 is the most common type and is mainly associated with hyperimmunoglobulin G4, anti-nuclear antibody, anti-smooth muscle antibody, anti-lactoferrin antibody, and anti-carbonic anhydrase antibody. Type 2 is not associated with either specific autoantibodies or extra-pancreatic manifestations. There are three recognized patterns of autoimmune pancreatitis: diffuse, focal, and multifocal<sup>2</sup>. Diffuse disease is the most common type, with a diffusely edematous sausage - like appearing pancreas with well demarcated sharp margin and absence of the surface undulations. In comparison to diffuse pattern, focal disease is less common and manifests as a focal mass, often with involvement of the pancreatic head. This appearance is can resemble that of

pancreatic malignancy. Focal disease tends to be relatively well demarcated, and, when present, upstream dilatation of the main pancreatic duct is typically milder than in patients with pancreatic carcinoma<sup>3</sup>. There are several established diagnostic criteria systems for auto immune pancreatitis in literature. These are mainly based on imaging, histologic pattern, serologic findings and extra pancreatic involvement (biliary, renal and retroperitoneum involvement). Some systems also take into account the response to cortico steroid therapy. Asian 2008 AIP diagnostic criteria is one of the accepted systems as mentioned below.

### Imaging findings

CT
Diffuse or focal enlargement of the pancreas with loss of surface undulations.
Peri pancreatic rim of halo
Focal mass in the head and uncinat process that may mimic pancreatic malignancy.
Peri pancreatic fat stranding with inflammatory thickening confined to the peri pancreatic region.
MRI
T1 : Hypointense
T2: Mildly hyperintense
T1 C + Gd : Delayed enhancement of the peri pancreatic rim suggesting its sclerosing component.
DWI : Increased DWI signal noted in the affected regions.
ADC : Low ADC signals noted in the affected region - $0.7 \times 10^{-3}$ .

## REFERENCES

1. Kim KP, Kim MH, Song MH, Lee SS, Seo DW, Lee SK. Autoimmune chronic pancreatitis. Am J Gastroenterol. 2004;99:1605–16.
2. Sahani DV, Kalva SP, Farrell J, et al.. Autoimmune pancreatitis: imaging features. Radiology 2004;233(2):345–352. Link.
3. Kamisawa T, Egawa N, Nakajima H, Tsuruta K, Okamoto A, Kamata N. Clinical difficulties in the differentiation of autoimmune pancreatitis and pancreatic carcinoma. Am J Gastroenterol 2003;98(12): 2694–2699. CrossRef, Medline.
4. tsuki Makoto. “Asian diagnostic criteria for autoimmune pancreatitis: consensus of the Japan-Korea Symposium on Autoimmune Pancreatitis.” Journal of Gastroenterology 43, no. 6 (January 1, 2008): 408.

Source of Support: None Declared  
Conflict of Interest: None Declared