International Journal of Recent Trends in Science And Technology, ISSN 2277-2812 E-ISSN 2249-8109, Volume 2, Issue 4, October to December, 2012 pp 53-54

Anomalous Anterior Cerebral Artery

Kardile Poorwa Baburao[1], Ughade Jaideo Manohar[1*], Ughade Manohar Namdeo[2], Sudhir Vishnupant Pandit[3]

{[1]Assistant Professor, [3]Associate Professor} Dept. of Anatomy, Shri Vasantrao Naik Govt. Medical College, Yavatmal (MS) INDIA.

[2]Professor and Head, Dept. of Anatomy, A.C.P.M. Medical College, Dhule (MS) INDIA.

[*]Corresponding Address:

drjaideoughade@gmail.com

Case Report

***Abstract*:** The variation in the anterior part of the circle of willis is quiet rare and finding multiple variation in single case is still rare. During routine dissection we noted multiple anomalies in form of hypoplasticity, duplication and persistence of embryonic pattern in the form of azygous artery in the right anterior cerebral artery. Any variation in the vessels of circle of Willis influences the change in the haemodynamics of blood supply to the brain. such variations also play a great role in the decision of line of management of the patient. The awareness of this rare anatomical variant is important considering today advanced imaging modalities and give consideration to its potential serious complications with fellow clinicians.

***Keywords*:** Anterior Cerebral artery, Circle of Willis, Splitting, hypoplastic artery, internal carotid artery

Introduction

The brain is supplied by branches from two vertebral arteries and two internal carotid arteries which forms an anastomotic circle at the interpeduncular fossa.

In the 17th century Thomas Willis described this arterial circle at the base of the brain which is known as Circle of Willis.[1]

Circle of Willis comprises of –

1) Right and Left Anterior cerebral arteries.
2) Anterior communicating artery.
3) Right and Left Posterior cerebral arteries.
4) Right and Left Posterior communicating arteries.

Thus the anterorlateral part of the circle is formed by the anterior cerebral artery which is joined from either side by anterior communicating artery[2].

The paired anterior cerebral arteries arise from the internal carotid arteries and then supply mainly the medial surface of each cerebral hemisphere.

Many anatomical variations have been reported on the posterior cerebral and posterior communication arteries. However variations encountered in the anterior portion of the circle are relatively rare.[3] These exceedingly rare anatomical variations have very important implications for potential neurological, radiological and neurosurgical conditions[4].

Material and Method

During routine dissection conducted on 70 years old embalmed male cadaver in Anatomy department, Shri Vasantrao Naik Govt. Medical College, Yavatmal; we encountered an anomalous anterior cerebral artery. The calvarium was sawed and the cranial cavity was opened. Necessary precautions were taken to avoid distortion of the internal structures. Once the calvarium was removed, the dura was opened. The brain was detached. The intact brain thus removed from the cranial cavity was fixed in 10% formalin. The dura mater and arachnoid mater were carefully dissected out from base of the brain to expose the circle of willis.[5] The length and diameter of variant anterior cerebral arteries were measured by Vernier caliper and photographed.

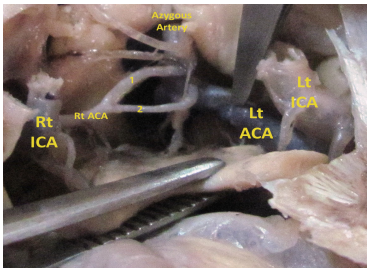

Figure1: Anomalous Anterior Cerebral artery.
(ACA – anterior cerebral artery, ICA – internal carotid artery, 1 – upper branch, 2 – lower branch)

Result:

The length of right Anterior cerebral artery was 5 mm and its diameter was 0.4 mm. Thus the right Anterior cerebral artery was hypoplastic (diameter less than 0.5 mm). The trunk of right Anterior cerebral artery after a short distance bifurcated into two branches. The two branches were not exactly parallel to each other. They formed a loop. No structure passed through the loop. Its communication with left Anterior cerebral artery was Y-shaped (forked). Apex (main stem) was towards the origin i.e. right Internal carotid artery. The branches of right Anterior cerebral artery were hypoplastic, the upper branch 1 was 3.8 mm in length and its diameter was 0.4 mm. The lower branch 2 was 4 mm in length and diameter was 0.3 mm. Both the arteries united with left ACA at separate points.

The left Anterior cerebral artery was 11 mm in length and its diameter was 4 mm. In the longitudinal fissure the right and left anterior cerebral arteries fused to form a single trunk azygous artery.

Discussion:

The haemodynamics of the circle is influenced by variations in the length and calibre of individual vessel of the circle of Willis[6]. In the present study bifurcation of right anterior cerebral artery was noted. Study of Kapoor K[7] and Vare et al[8] showed splitting as most common variation (5%) of anterior cerebral artery. Splitting of vessel occurs as early process of development is characterized not by the overgrowth of definite vessels but by elaboration of certain channels, and the disappearance of others in the primitive plexus. Some abnormal branches may sprout leading to duplication. Various authors have used the term hypoplastic to define condition in which the external diameter of a vessel is less than 1 mm. Padget (1948)[9] noted that external diameter of all the component vessels in normal mature brains should be more than 1 mm. Similar to present case hypoplasticity of the anterior cerebral artery have been reported by Alper et al (1959)[10], Battacharji et al (1967)[11], Puchades-Orts et al (1976)[12].

In the present study fusion of both anterior cerebral arteries into single azygous artery for a short distance is considered as persistence of lower primate pattern.It is found as a typical pattern in dogs and monkeys. Barkow (1866)[13] described a case in which the anterior cerebral arteries fused to form single trunk, a condition found constantly in lower mammals. Baptista (1964)[14] distinguished the Azygous anterior cerebral artery from other variants as the unpaired anterior cerebral artery and observed it in only one case.

Conclusion:

This case is a very rare anatomical variant bearing in consideration the alteration of arterial hemodynamics of the frontal lobe and the increased incidence of saccular aneurysms and arterio-venous malformations. An awareness of such variations is important in preserving the vessel from injury during various neurosurgical processes. It also useful for the radiologist to be aware of such multiple variations to pin point the exact anomalies[4].

References

Corresponding Author

Dr Jaideo Manohar Ughade,
'MANOHAR', Bunglow no 49,
Madhuban Colony, Dhamangaon
Road, Yavatmal.
drjaideoughade@gmail.com

1. Feindel W. Men and books: Thomas Willis - The founder of Neurology. Can Medical association Journal 2004; 87: 289-96.
2. Gray H; Grays Anatomy: The Anatomical Basis of Clinical Practice, 40th edn. Elsevier Churchill Livingstone, 2008, pp 251-252.
3. Wiseoff JR, Flamm ES. Aneurysm of the distal anterior cerebral artery and associated vascular anomalies. Neurosurgery 1987; 20(5): 735-741.
4. Jennings S, Ali H. Case report: the clinical significance of an azygous anterior cerebral artery .International Journal of Anatomical Variations. 2011; 4: 185–187.
5. Romanes GJ, Cunningham's Manual of Practical Anatomy. The cranial cavity. 15thEdn. vol 3. Oxford Medical Publication. 2008, pp 43-44.
6. Poudel PP, Bhattarai C. Anomalous formation of the circulus arteriosus and its clinico-anatomical significance. Nepal Med Coll J. 2010;12(2):72-75.
7. Kapoor K, Singh B, Dewan I. Variations in the configuration of the circle of Willis. Anatomical Science International 2008; 83: 96-106.
8. Vare AM, Bansal PC. Arterial pattern at the base of the human brain. Journal of Anatomical Society of India. 1970;19(3):71-79.
9. Padget DH. The circle of Willis: Its embryology and anatomy. Intracranial Arterial Aneurysms,Chapter III (Dandy WE,ed.). Comstock Publishing, New York. 1948, pp67-90.
10. Alper BJ, Berry RG, Paddison RM. Anatomical studies of the circle of Willis in normal brain. Arch Neurology Psychiatry. 1959;81:409-418.
11. Battacharji SK, Hutchinson EC, McCall AJ: The circle of Willis - The incidence of developmental abnormalities in normal and infracted brains. Brain 1967;90:747-758.
12. Puchades-Orts A, Nombela-Gomez M, Ortuno PG. Variations in the form of circle of Willis: Some anatomical and embryological considerations. Anatomical Rec. 1976;185,119-123.
13. Barkow HOL, Schlagad.der Saugethiere 1866, Taf.43, quoted by Mitchell SW, and Dercum FX, Aneurysm of an Anomalous Artery causing Antero-posterior Division of Optic Nerves and producing Bitemporal Hemianopsia," Journ. of Nerv. and Ment. Dis, vol. xiv., 1889.
14. Baptista AG. Studies on the arteries of the brain. The anterior cerebral artery: some anatomic features and their clinical implications. Neurology 1963;13:825-835.